1917
B19

Baldwin

Pharyngeal Derivatives of Amblystoma

PHARYNGEAL DERIVATIVES OF AMBLYSTOMA

BY

FRANCIS MARSH BALDWIN

A. B. Clark College, 1906.
A. M. Clark University, 1907.

THESIS

Submitted in Partial Fulfillment of the Requirements for the

Degree of

DOCTOR OF PHILOSOPHY

IN ZOOLOGY

IN

THE GRADUATE SCHOOL

OF THE

UNIVERSITY OF ILLINOIS

1917

1917
B19

UNIVERSITY OF ILLINOIS

THE GRADUATE SCHOOL

May 5 1917

I HEREBY RECOMMEND THAT THE THESIS PREPARED UNDER MY SUPERVISION BY Francis Marsh Baldwin

ENTITLED Pharyngeal Derivatives of Amblystoma

BE ACCEPTED AS FULFILLING THIS PART OF THE REQUIREMENTS FOR THE DEGREE OF Doctor of Philosophy

J. A. Kingsley
In Charge of Thesis

Henry W. Ward
Head of Department

Recommendation concurred in:*

Madison Bentley
Frank Smith
Charles Zeleny

Committee on Final Examination*

*Required for doctor's degree but not for master's.

376584

UIUC

CONTENTS.

Page.

I. Introduction..... 1

Material and Methods..... 2
II. Observations..... 3

Development and adult conditions of pharyngeal structures.....
1. Thymus bodies..... 3
A. Larvae 8mm.long..... 3
B. Larvae 9.5mm.long..... 6
C. Larvae 10-12mm.long..... 8
D. Larvae 13-15mm.long..... 12
E. Larvae 19-20mm.long..... 13
F. Larvae 25-45mm.long..... 15
G. Transforming larvae. 17
H. Thymus gland of adult..... 19
2. Thyreoid gland..... 21
A. Larvae 5mm.long..... 21
B. Larvae 8mm.long..... 23
C. Larvae 9.5-11mm.long..... 25
D. Larvae 13mm.long..... 28
E. Larvae 15mm.long..... 29
F. Larvae 19mm.long..... 31
G. Larvae 26mm.long..... 33
H. Larvae 35mm.long..... 33
I. Larvae 39mm.long..... 34
J. Larvae 45mm.long..... 34
K. Larvae transforming..... 34
L. Thyreoid gland of adult..... 37
3. Postbranchial body..... 40
A. Larvae 8mm.long..... 40
B. Larvae 9.5mm.long..... 41
C. Larvae 10-11mm.long..... 42
D. Larvae 13-15mm.long..... 43
E. Larvae 19-20mm.long..... 43
F. Larvae 26mm.long..... 45
G. Larvae 35-40mm.long..... 45
H. Late larval, and early transforming larvae... 46
I. Late transforming larvae..... 47
J. Postbranchial body of adult..... 47
4. Carotid gland and epithelial bodies..... 49
A. Transforming larvae..... 50
B. Adult structures..... 52
III. Review of the literature..... 54
A. Concerning structures in Amphibians..... 54
B. Concerning structures in other Vertebrates.. 67
IV. General Summary..... 73
V. Bibliography..... 79
VI. Description of Plates and Figures..... 84
VII. Vita..... 89

Pharyngeal Derivatives of Amblystoma.

by
Francis Marsh Baldwin.
Zoological department, University of Illinois.

I. INTRODUCTION.

The recognition, within recent years, of the parts played by certain of the structures arising from the walls of the human pharynx, in health and disease, renders these bodies of great importance, and hence, every fact which throws light upon their morphology is of value. It was from such considerations that the study detailed below were outlined, for, while a knowledge of their development and structure in amphibia, may have no immediate practical value, the close relations of that group to the ancestors of the mammals gives every addition to our knowledge an interest which would not be expected with such groups as the teleosts and birds.

The literature of the subject, while not great, is rather difficult to follow, because of the lack of unanimity of opinion as to homologies, and also from the conflicting nomenclature of the subject, the same structures often having different names, even in the same minor group. In some groups pharyngeal derivatives are found which apparently do not occur in the amphibia or at least in the urodeles. These have not been considered here, and the present work is restricted to the series of 'glands' etc., which are developed in the pharyngeal region of Amblystoma, the list including the thyreoid, and thymus glands; the so-called postbranchial body; the so-called epithelial bodies or gill-remnants; as well as the carotid gland, although it is not a true pharyngeal derivative.

Since but little recent work has been done on the developmental side of these structures in amphibians--Maurer ('88), Livini ('02), Greil ('02-06) and Marcus ('08) excepted--a detailed study of their morphogenesis in Amblystoma has some value.

Digitized by the Internet Archive
in 2013

http://archive.org/details/pharyngealderiva00bald

The work has been carried on in the Zoological laboratory of the University of Illinois, under the direction of Professor Kingsley, to whom the writer is deeply indebted for invaluable aid during its prosecution. My thanks are also due Professor Ward, for laboratory facilities and numerous other courtesies.

Materials and Methods: This research is chiefly based upon the study of serial sections of larvae of Amblystoma punctatum, beginning with 5mm. stage, and including successive stages through the 45mm. larvae, and following these with stages in transformation, and sections of adult heads. Supplementing the study of the slides, gross dissections were made of adults, using Amblystoma tigrinum as a basis. The young larvae were fixed in Smith's fluid, stained in toto in Borax-carmine, dehydrated, embedded and mounted in the usual way; older larvae and adult heads were fixed in formalin (heads decalcified), dehydrated, embedded, sectioned and doubly stained on the slide with Borax-carmine and Lyon's blue.

For stages in metamorphosis, I am greatly endebted to Professor Kingsbury of Cornell University, for the use of his excellent slides, and my thanks to him for his kindness are here given. The figures representing the various structures are drawn by the aid of the camera lucida. The following list gives briefly the structures and stages reconstructed in wax:

Thyreoid: 8, 9.5, 11, 19, 39mm. larvae; and early transforming stage.

Thymus: 19, 35mm. larvae; and early, late transforming; and adult stages.

Postbranchial body: 19, 40mm. larvae; and early transforming stage.

Epithelial bodies: late transforming and adult stages. (these appear only at the time of transformation).

Carotid gland: late transforming and adult stages. (this gland appears during the time of transformation).

II. Observations.

1.Thymus bodies.

A. Amblystoma larvae, 8mm. long.

At the 8mm. stage,(figs.4 and 5) the mouth is not open,the place where it is to form being occupied by an extensive oral plate,in which the exact limits of entoderm and ectoderm can be recognized only uncertainly and with difficulty (see Kingsley and Thyng '04,and Johnston '10). The pharyngeal lumen (ph.) extends forward into this plate from behind. The pharyngeal region is a flattened tube throughout. It gives off on either side,the visceral pouches-- the future gill clefts--which have not yet broken through. The most anterior of these pouches,the hyomandibular,lies about the level of the eye in the series on which these observations are based. Externally it has a length (in the longitudinal direction of the animal) of about 40 mu. The outer surface of the entodermal walls do not quite reach the external ectoderm of the head,while below and in front of it is a mass of mesoderm,the ventral prolongation of the third somite of the head. A conical projection,consisting of a few cells at the posterior dorsal angle of this pouch is the anlage of the first thymus body. The projection is some distance from the ectoderm,between which and the anlage are cells,some of which stain more darkly than the surrounding cells. These darker cells are apparently those cells which Drüner has interpreted as the ectodermal contribution to this thymus body and concerning which more will be said below.

This first thymus anlage,(fig.6)lies about mid-way between the eye and the ear. Dorsal to it is the developing facial (VII) ganglion,while the internal carotid artery (i.c.) lies medial to it and sends a small twig,(the quadratomandibular artery) forward and ventrally to supply the anterior region of the body,the latter passing just in front of the thymus anlage. The anlage on the left is seen in three,and the one on the right,in four successive sections (each 10mu),but it is difficult to limit its extent exactly.

The second pouch (first branchial) is much like the hyomandibular in its general features. Externally it extends in the longitudinal direction of the body about 200mu, measured from the caudal side of the hyomandibular pouch and ending with the caudal, lateral projection, just under the anterior wall of the ear. The anlage of the second thymus body is formed from the dorsal angle of this pocket at its caudal extremity, in the same way as the first body was formed from the hyomandibular pouch. This anlage, (t_{II}, fig.8) is not as well defined as the first, so that it is difficult to fix its exact limits. The conical projection is pronounced in but a single section, but it is probable that cells of entoderm in front and in back of this contribute to its formation. In addition to the dorsal region, the lateral region of this pouch thickens and extends toward the ventro-lateral wall where the ectoderm is to split to form the first (br.1) branchial cleft. The anlage of the body, as noted above, lies just below the anterior wall of the ear; the glossopharyngeal (IX) ganglion, and the internal carotid artery are medial to it. Near the anlage of the second thymus body are numerous more darkly stained cells, similar to those mentioned in connection with the first thymus body. In the ventral region of the body, the structures are not clearly defined, although the pericardium and the truncus arteriosus are recognizable.

The third pouch (second branchial) is nearly 160mu long, its caudal extremity lying just posterior to the ear. The anlage of the third thymus body, (t_{III}, fig.9) is formed by a lobe of cells directed dorsally from the distal tip of this pouch, the lateral portion of which extends toward the ectoderm of the body wall to form the second (br.2) branchial cleft. This anlage is more clearly defined than that of the second, and occurs in three successive sections (each 10 mu). The vagus (X) ganglion is just above this anlage, the more darkly stained cells of Drüner intervening between the two. The pericardial chamber in the ventral region of the body is here of considerable size, and the

heart is flexed.

The anlagen of the fourth and fifth thymus bodies (t_{IV}, t_V, figs., 10 and 11), are formed in a similar way as solid outgrowths from the dorsal extremities of the fourth (third branchial) and fifth (fourth branchial) pouches respectively. The fourth pouch is about 70mu long, and the fifth, about 40mu; these two being now comparatively close together. The anlage of the fourth thymus body is fairly well defined. It is a lobate body, about 20mu in diameter, extending dorsally from the caudal dorsal end of the third pouch and in one section shows a tendency to be constricted from the other cells of the pouch. The darker cells are somewhat more compact about the dorsal tip of this anlage, than in the case of the others. The vagus (X) gnaglion is dorsal and a little medial to the fourth anlage, while below and medial to it are the pericardial chamber and the heart. It is difficult to determine the exact extent of the anlage of the fifth thymus body. It is a lobate, illy defined mass of cells extending in a dorsal direction from the fourth branchial pouch towards the lateralis ramus (L.) of the vagus nerve.

The general positions of the thymus anlagen at this stage in Amblystoma agree in most essentials with the description of the bodies in Siredon and Triton by Maurer ('88), and in Siredon by Drüner ('04) and Maximow ('12). Concerning the interpretation of the darker cells which are found in close proximity, dorsal and lateral, to the bodies there is some differences of opinion. Drüner ('04), in his work on Siredon, was the first to suggest that they are derived from the ectoderm, and that they contribute to the formation of the thymus bodies. To these groups he gave the name 'Ektodermzapfen'. Maximow, ('12), p.573, however finds them, (der Drüner'schen Thymus ectodermalis) very sharply set apart from the thymus bodies, and more closely associated with the anlagen of the nerve ganglia of the different regions. He says, "Ob diese Zellansammlungen wirklich dem Ektoderm entstammen, wie es Drüner will, vermag

ich nicht anzugeben; jedenfalls hängen sie alle unmittelbar oder durch einen kürzeren oder längeren Zellstrang mit der Masse der betreffenden Gehirnganglien zusammen und sind von deren Zellen nicht scharf abzugrenzen". In my material, it is far from certain that there is any such ectodermal contribution as Drüner claims. I find,indeed, cells differing in staining reaction,from those of the other entodermal cells in this very region,but I can trace no connection of these at any stage with the ectoderm. In addition,at no time in the subsequent stages do these darker cells,so far as I am able to judge,unite either directly with the thymus bodies,or the nerve ganglia,and therefore,I find no good reason for regarding them as other than mesodermal cells of the region.

B. Amblystoma larvae, 9.5mm.long.

In 9.5mm. larvae,the mouth is not yet open,but the pharyngeal pouches have extended laterally so that the entoderm of their distal wall has fused with the cells of the ectoderm of the body,although the clefts are still closed. The pharyngeal entoderm is now lighter in color,due to its less amount of yolk content,so that the morphological relationships of parts are more easily followed.

The anlage of the first thymus body,(fig.12,)has not greatly changed in its relative position. The first pouch (hyomandibular) has extended laterally and at the same time a little caudad,the thymus body being carried a corresponding distance in the same direction. It is now a somewhat spherical knobule of entodermal cells, (about 30 mu in diameter),still connected with the dorsal wall of the pouch,extending dorsally just lateral to the facial (VII) ganglion. Of three successive sections which pass through it,only in the second is it connected with the pouch by a thin stalk of cells. The internal jugular vein is just above,while the internal carotid artery is medial to it. The darkly staining cells of Drüner form a somewhat loose mass between it and the facial nerve. In front of the thymus,the internal carotid artery sends the mandibularis branch to the region of the jaw,while caudad to it,the facial ganglion gives off two

rami; one (ramus palatinus) courses medially, the other, a large single trunk (which breaks up into the ramus hyo-mandibularis, the ramus alveolaris and buccalis) passes laterad and enters the jaw region. (see Herrick; Strong; Coghill).

The second pouch (first branchial) is much like the first, its caudal portion meets the ectoderm of the side of the body, below the posterior wall of the ear, where the gill cleft is to open. The anlage of the second thymus body in this stage, is a group of cells, (fig.14, t_{II}) similar in color to those of the dorsal wall of the pouch from which they have been separated. This group is located well to the side of the body, in the region of the glossopharyngeal ganglion and lies equidistant between the medial surface of the levator arccum branchiarum muscle of the first gill arch, and the internal jugular vein. It is just in front of the point where the pretrematic ramus of the glossopharyngeal nerve enters the gill arch. The body is almost spherical in shape, and is about 30 mu in diameter. The darkly stained cells are now less in evidence; only one or two appear in each section.

The caudal region of the third pouch (second branchial) lies about 90mu caudad to the second. The anlage of the third thymus body (t_{III}, fig.15) is not yet completely separated from the dorsal cells of the pouch, being held by a very narrow connecting stalk of cells. This body is very small, being only between 15 to 20 mu in diameter. It lies just posterior to the second efferent branchial artery on its course from the arch to the radix aorta. Caudad to the gland, the first branchial nerve of the vagus passes into the arch. The jugular vein lies in the same relative position as before, but the internal carotid artery does not extend as far back as this region. The darkly stained cells in the region of this thymus body have disappeared. Maximow found the third thymus body in Siredon, 9.5mm. long, free in the mesenchyme, dorsal to the dorsal wall of the pharynx, and in close connection with the vagus ganglion, and medial to the large muscle ('wahrscheinlich den M. levatores arcuum branchialium'), and somewhat

larger (40mu in diameter) than the one I have described in Amblystoma of this stage.

The caudal extremities of the fourth and fifth pouches (third and fourth branchial) are more dorsal in position than any of the others, so that the points from which the fourth and fifth thymus bodies develop, lie above the level of the notochord, and close under the dorso-lateral wall of the larval body.

The caudal distal extremity of the fourth pouch, from which the fourth thymus body is developed (t_{IV}, fig.16), lies 60mu caudad to the third thymus body. Its anlage is an elongated, ovoid group of cells still in connection with the dorsal portion of the pouch. It is between 35 and 40 mu in diameter and lies just ventro-medial to the levator arcuum branchiarum of the third arch, in the region of the vagus ganglion.

The anlage of the fifth thymus body (t_V, fig.17), is a small bean-shaped group of cells still in connection with the caudal distal end of the fifth pouch (fourth branchial) and is 120 mu caudad to the fourth body. It is about 20 mu in diameter, and protrudes dorsally into the space between the levator arcuum branchiarum muscle of the fourth arch, and the medially placed dorso-laryngeus muscle. Since the pouch from which this body is derived has been pushed laterally and caudally as noted above, its caudal extremity in section is completely separated from the central pharyngeal tube. In the intervening space, the internal jugular vein passes ventrally, and medial to the vein, the strands of the dorso-laryngeus muscle extend from the region of the larynx to the lateral wall of the neck region. The small lateralis ramus of the vagus nerve passes backward just above the anlage of the thymus body, the scattered darkly stained cells lie in the space between.

C. Amblystoma larvae, 10 to 12mm. long.

Since larvae of these lengths are very similar in developmental details, a single description of the thymus bodies in them will answer for all. Growth

has been rapid, so that parts which were in the earlier stages, only outlined as loose cell masses, are now well defined. This rapid development has its effect upon the thymus bodies as well as the other organs and tissues, so that some irregularities occur in their size, shape and general position.

The first thymus body, which was a bulb of cells connected with the pharynx in the 9.5mm larvae, is now (fig.18), reduced in size, and although still attached to the pharyngeal wall, it protrudes dorsally as a finger-shaped stalk just ventral to the facial ganglion and medial to the posterio-lateral surface of the quadrate anlage. Its distal end is now even smaller than its stalk, the whole body being only about 20mu in thickness, and occurs in but two successive sections. The mandibular trunk of the internal carotid artery passes to the lateral region of the jaw just cephalad of the thymus body, and the hyo-mandibular ramus of the facial ganglion passes to the region of the jaw just caudad to it.

This finger-shaped anlage, (fig.19) is composed of numerous large, loosely packed epithelial cells, separated by a light gray matrix, similar in size and shape to the cells of the pharynx with which they are in intimate relation. They are surrounded by a thin membrane--a sort of membrana propria--apparently a continuation of that of the upper surface of the pharyngeal wall. It is evident that this body is undergoing degeneration. Maurer found the body on both sides, in an Axolotl 1cm. long, reduced to two or three yolk-filled cells completely cut off from the pharynx and lying in the connective tissue in about the same relative position as in Amblystoma. He says, "die erste Knospe ist recht wie links in Rückbildung begriffen, in dem an ihrem Platze jederseits nur zwei bis drei, Dotterblättchen enthaltende, rundeZellen liegen". Maximow ('12), however, in 10mm. Siredon larvae found the body still in connection with the pharyngeal epithelium, occupying a position ventral to the anterior wall of the ear, between the quadrate anlage and the facial ganglion. "Sie war in einem solchem Fall auf neun aufeinanderfolgenden Schnitten von 8u Dicke zu sehen und

war hier sogar noch mittelst eines dünnen Stiel mit dem Pharynxepithel verbunden". On the other hand, he found the body reduced in 11mm.larvae, to several irregular epithelial cells completely separated from the pharynx and which occured in only 2 or 3 serial sections. Drüner, in 11-15mm. stage of Siredon, found the first body still in contact with the pharyngeal cells. He says, "Bei 11-15mm.langen Exemplaren bleibt als Rest derselben noch ein feiner, aus wenigen Zellen bestehender Strang ubrig----liegen.

The second thymus body in 10mm. larvae, is not readily found, as it is reduced to a group of loose epithelial cells having the yolky character, situated just cephalad and a little medial to the point where the post trematic branch of the glossopharyngeal nerve enters the gill arch. These cells, on the right side of the body, are four or five in number and occur in but two successive sections (10 mu each), and are closely applied to the nerve tract. I am unable to find cells corresponding to these on the left side, in 10mm.larvae. In 11mm. larvae, no trace of the second thymus body is found on either side of the body.

The third thymus body in 11mm.larvae (on either side of the body) is free from the pharyngeal entoderm, and lies as a rather compact mass in the connective tissue, dorsal to the cartilage anlage of the second gill arch, and medial to its levator arcuum branchiarum muscle, just caudad to the posterior wall of the ear. The body is a very small spherical mass of epithelial cells, between 25-35mu in diameter. It is composed of several (5 to 9) large epithelial cells separated from each other by a considerable amount of inter-cellular substance, there being no sharp marginal membrane. Although, aside from these general observations, no attempt is made here to describe the histological relationships of the constituent parts of the thymus bodies, it is of interest to note in this connection, the results of Maximow's work on this body in 10-11mm. Siredon larva, since the facts in Amblystoma accord very closely to the description given by him in that form, p.578.

"Nachdem sich die Knospen abgeschnürt haben, sieht man aber im Folgenden, dass der histologische Charakter des Thymusepithels und des Pharynxepithels bald sehr verschieden wird. Was das Pharynxepithel betrifft, so sind schon bei 10.5mm. langen Larven die Dotterkörnchen darin viel spärlicher als früher und die Zellen selbst sind infolge rascher Wucherung kleiner geworden; ihre Grenzen sind viel deutlicher-------".

"Die Epithelzellen der Thymusknospen bewahren hingegen das ursprüngliche Aussehen viel länger. Die Wucherung verläuft hier zunächst sehr träge, Mitosen sind vorerst nur äusserst selten zu finden. Zellgrenzen sind nicht zu unterscheiden und die ganze Knospe sieht wie eine einheitliche Protoplasmamasse aus, die durch und durch mit groben, verscheiden grossen Dotterkörnchen erfüllt ist, zwischen denen eckige, stark deformierte, blasse Kerne zusammengepresst liegen. Die Kerne werden mit der Zeit noch etwas heller, besonders im Vergleich mit den Kernen der Mesenchymzellen, weil ihre Chromatinteilchen feiner und spärlicher werden und auch die Nukleolen an Grösse abnehmen. Die Kernmembran ist äusserst zart und ihre Konturen sind zwischen den Dotterkörnchen nicht überall genau zu definieren. Zwischen den letzteren liegen einzeln oder Häufchen Pigmentkörnchen zerstreut. Eine Membrana propria fehlt an der Oberfläche der Thymusknospen vollständig---man sieht hier keine scharfe Begrenzungslinie".

The fourth and fifth thymus bodies are similar in character, size and position (on the two sides of the body), to that of the corresponding bodies in 10mm. larvae, and like them, these are completely cut away from their respective pouches, and lie as small rounded masses embedded in the connective tissue close to the lateral wall of the body. The fourth is 60mu caudad to the third and is almost spherical, being about 30mu in diameter. The fifth is some distance caudad (about 120mu) to the fourth and is slightly oval in form extending through three successive sections, having a minor diameter of 20mu. In both fourth and fifth bodies, the epithelial cells retain the light yolky character of the cells

of the pharynx and there is no well defined outer membrane.

D. Amblystoma larvae, 13-15mm.long.

Except for the persistence of the anlage of the first body on the right side in one larva 13mm.long, both the first and second thymus bodies on either side have now degenerated. The persisting anlage is reduced to a short finger-shape stalk of cells extending dorsally from the pharynx at a point between the medial ventral surface of the quadrate cartilage and the facial ganglion, just under the anterior wall of the ear. Its epithelial cells are small and thinly scattered, and the light yolky character had disappeared. In the 15mm. larva, the degeneration of the first two bodies is complete, no trace of them being found in subsequent stages. This early degeneration of the first two bodies in Amblystoma, agrees in the essential points with facts recorded by Maurer ('88), in Axolotl, and Drüner ('04) in Siredon, and Maximow ('12) in Siredon. Drüner however, found an epithelial follicle in two of his later stages, (36mm.) which he interpreted as remains of the first thymus body. He also found a similar follicle in an older larva (the exact length of which he does not state). He says, p.567, "Nur selten bildet sich ein kleines Epithelbläschen oder---häufchen aus ihren Resten, welches hinter dem Quadratknorpel der oralen Seite des Facialisstamms, da wo er sein Ganglion verlässt, anliegt. So fand ich es bei zwei 36mm. langen Larven. Auch bei einer ältern Larve fand ich ein solches Bläschen einmal bei der Präparation". Careful examination of the region of the first thymus body in Amblystoma in subsequent stages has thus far failed to show such a follicle as Drüner describes.

Shiftings of the surrounding parts, due to growth, are taking place more slowly now, so that the third, fourth and fifth thymus bodies are relatively little changed in position. All are round or slightly oval in form, and vary slightly in size from each other and from their fellows on the opposite side of the body.

The margins of the bodies, as in the earlier stages, are not well defined, the cells being embedded in an inter-cellular matrix, there being no membrana propria The yolky character, so conspicuous in the early stages is now rapidly disappearing being replaced by a more darkly staining substance, and the large epithelial cells have divided into numerous smaller ones.

The third body, (about 100mu caudad to the ear) is almost spherical, about 40mu in diameter, and is slightly flattened dorso-ventrally. It has moved slightly dorsally and laterally, so that it lies dorsal and lateral to the cartilage of the first branchial arch, and immediately to its levator arcuum branchiarum muscle.

The fourth body is close behind the third, (about 40 mu) but is a little dorsal and medial to it, directly above the second branchial cartilage and lateral to its levator arcuum branchiarum muscle. Like the third, it is almost spherical, varying in diameter between 37 and 43 mu.

The fifth body is some distance (about 110 mu) caudad to the other two, and is more dorsal than either, lying close to and a little above the level of the middle region of the brain. It is oval and measures 44x53mu.

E. Amblystoma larvae, 19 or 20 mm. long.

Since the thymus bodies take positions which remain practically constant for all succeeding larval stages and their morphological relationships are well defined, the description is given in some detail. As a basis for this I use a wax model of a 19mm. larva.

The three bodies have increased somewhat in size, but retain, on the whole, their general spherical or slightly oval form. The third and fourth are close to each other (about 95mu apart), the fifth however, is quite a distance caudad to these two (nearly 285mu). The fact that the fifth body is relatively farther caudad to the fourth, than the fourth is from the third is noted both by Maurer ('88, Axolotl) and Maximow ('12, Siredon); neither however give the exact distances.

A dorsal view of the reconstructed parts, showing the three thymus bodies on the right side of the body is shown in fig.41. In size, the third and fourth bodies are about equal, being 90x75mu and 75x60mu respectively, while the fifth is somewhat larger than either, measuring 90x 130 mu. It is interesting to note here that the fifth body in Amblystoma at this stage of development is nearly the same size as that given for the fifth body in 17mm. Siredon larva described by Maximow (136x87mu). The other two however are a little smaller in Amblystoma than those of Siredon.

The third thymus body, (fig.26) begins 140mu caudad to the posterior wall of the ear, where it lies in the connective tissue in the region above the pharynx, a little medial and anterior to the posterior caudal tip of the cartilage of the first branchial arch. The first efferent branchial artery emerges from the medial surface of the first branchial cartilage near its caudal tip, and passes forward and medially, coursing just below the third thymus body, and, after giving off the internal carotid artery, turns medially to become the radix aortae. A little ventral to the anterior end of the thymus body--between it and the blood vessel just described-- the glossopharyngeal (IX, fig.41) nerve passes to the lateral surface of the caudal tip of the first branchial cartilage, where it divides into its pre-and post-trematic nerves. In a similar manner, a ramus (the first branchial nerve of the vagus, n_1,) passes laterally, caudad and a little ventrally to the posterior end of the third thymus body, and breaks up into its pre-and post-trematic branches.

The fourth thymus body(fig.27), bears the same relation to the caudal tip of the cartilage of the second branchial arch, as the third thymus body does to the first, but, since the arches turn upwards and inwards at their caudal extremities, this thymus body is a little higher as well as a little more medial in position. The second efferent branchial artery passes from the medial surface of the caudal tip of the second arch, just back of and a little below the fourth thymus body,

and courses medially to join the radix some distance in front. The second branchial nerve (n_2) of the vagus, passes into the gill region just back of the caudal end of this body.

The fifth thymus body (fig.28) is somewhat dorsal and caudal to the junction of the third and fourth branchial cartilages at their most caudal ends, and since these are directed medially as well as dorsally (see also fig.41), this body has been forced into the space between them and the muscles, especially the dorso-laryngeus, d.l., muscle of the side of the neck. The lateralis nerve of the vagus passes caudad just medial to it.

All three bodies are similar in their histological appearance. They are loosely embedded in the connective tissue, the matrix of which is composed of fine fibres. Within the bodies, the margins of which are not clearly defined, are the larger epithelial cells and, in addition to these, numerous other cellular elements which conspicuously modify the general appearance of the bodies. Nearly all of the yolk has disappeared, and the cells uniformly take a darker stain. There is no membrana propria, the larger marginal cells being apparently held in place by a loose reticulum, which penetrates not only the spaces between the outer cells, but also extends inward throughout the spaces in the central area. The size and shapes of the epithelial cells differ in different sections. (For further detailed description of the histogenesis of the thymus bodies of this stage, refer to Maximow '12, 19mm. Siredon larva, p.597).

F. Amblystoma larvae, 25 to 45mm. long.

As noted above, the position of the thymus bodies in the succeeding larval stages up to metamorphosis (46mm.), changes but little so that only a brief consideration need be given them here.

There is little change in size and position of the bodies in a 26mm larva, from that just described. The third, on the right side, is almost spherical, about 90mu in diameter, and lies just dorsal to the first efferent branchial artery;

the fourth is slightly oval (87x75mu);and the fifth(110x130mu),lies some considerable distance caudad. No great difference in the histological appearance is noted here. In section,(fig.29)the fifth body (which is typical of the others also) has an outer layer of rather large epithelial cells,which enclose a central cavity of some size. There is no membrana propria,the cells being separated one from another by strands of connective tissue which extend into the cavity of the mass.

A wax reconstruction was made of the three bodies in the 35mm.larval stage of development,but this shows little difference,from that of the 19mm.stage. The bodies have increased in size;the fourth is larger than the third,and the fifth is the largest of all. The third is oval,and measures 102x92mu;the fourth is the same shape but larger 118x95;and the fifth (slightly flattened medially) is 135x 105x80mu. In histological appearance however,two noticeable changes have taken place. The epithelial cells are now much smaller and more numerous and except for the central area are scattered loosely throughout the mass (see fig.30). The outer margin of the mass is now surrounded by a loose connective tissue envelop,strands of which apparently pass between the small epithelial cells into the central cavity.

Aside from considerable increase in size no great difference is noted in the bodies in the 39-40mm.larvae. The three bodies are oval;the third being 200x155 mu;the fourth and fifth measuring 152x122mu and 175x135mu respectively.

In the last stage studies before the larva undergoes its transformation,(45 mm.long) all of the thymus bodies have increased markedly in length,but no great change in diameter has taken place. The third is now 220x164mu,and lies about 125mu caudad to the ear;the fourth is 180x240mumand the fifth is 285x350mu. Because of this increase in length,the caudal end of the third and the cephalic end of the fourth are close together (separated only about 40mu). These two lie caudad and a little lateral to the levator arcuum branchiarum muscle of the sec-

ond arch. The fifth is about 200mu caudad to the other two,it is somewhat elongate and its cephalic end is inserted into the space between the distal tips of the third and fourth branchial cartilages,and the medially placed dorsolaryngeus muscle,its caudal end tapering to a point close to the lateralis ramus.

G. Transforming Amblystomae.

The caudal extremity of the gill region in the early transforming larvae is undergoing most modification,so that the fourth and fifth (third and fourth branchial) clefts are closed,the pharyngeal entoderm of these persisting as mere rudiments. This readjustment of the caudal region of the gills has its effect upon the three thymus bodies,especially the fourth and fifth,which as earlier pointed out were intimately associated with these pouches in their genesis. The following description is based upon a wax model of the three bodies in this stage.

The third thymus body (fig.32) is 120mu caudad to the ear,and lies as an elongate,ovate body of considerable size (240x160mu) dorsal and a little medial to the caudal tip of the first branchial arch. As yet its relation to the blood vessels and nerves of the region is little changed,the first efferent branchial artery passes to the dorsal aorta from the gill just below it,and the rami of the glossopharyngeal and vagus nerves pass into the gill region,one in front the other behind the body. The condition of the pharyngeal pouches in this region however show that the clefts are closed to the outside.

The fourth thymus body (fig.33) is a smaller oval structure (150x100mu),and is nearly 180mu caudad to the third,but because of the reduction of the distal end of the second arch,it lies for the most part caudal to its posterior tip. The second efferent branchial artery,because of the transformation has moved forward,so that now its trunk leaves the medial side of the cartilage well in front of and below the thymus body. The pharyngeal entoderm which formed the

gill pouches (third and fourth branchial) is now reduced to two short blind tubes on either side, which extend caudally and laterally but a short distance from the central cavity of the pharynx. With the closure of the gill slits, and the reduction of the caudal extremity of the arches, the ramus of the vagus to this region has also disappeared.

Like the fourth, the fifth thymus body (fig.34) lies well dorsal, and for the most part caudal to the cartilage of the fourth arch. It is the largest of the three (360x120mu) and lies about 60mu behind the fourth.

In the late transforming stage, all of the slits are closed, their corresponding pharyngeal pouches being recognized as mere stubs of entoderm, and the branchial arches are rearranged to form the hyoid apparatus of the adult. As a result of this extensive shifting of parts by growth, the three thymus bodies have been forced somewhat caudad to the ear, the third being nearly 400mu from it, the fourth and fifth lying closely behind the third.

The third thymus body is now considerably flattened laterally, having been forced, in the shifting into the somewhat limited space above the first branchial cartilage, between the dorso-laryngeus and the trapezius muscles and the skin of the lateral surface of the body. It is about 240mu long (its long axis parallel to the long axis of the body), but is flattened laterally, its shortest axis is less than 100mu.

The fourth, similar in shape and position, is close behind the third, (only one or two sections intervene, about 60mu), but it is a little dorsal to the latter and is flattened against the dorso-laryngeus muscle. It is about 270mu long and 60mu in minor diameter, and somewhat narrowed at its cephalic end.

The fifth thymus body is close behind the fourth (about 60mu), and is flattened laterally and closely pressed against the muscles of the region. It is the largest of the three, discus-shaped measuring 500mu in its major, and about 75mu in its minor diameters.

H. The thymus gland of the Adult.

Since the thymus gland in certain adult Amblystomae has been the subject of several descriptions, from both the morphological and histological standpoints, (Simon,'45, Axolotl; Leydig,'52; Siebold and Stannius '56; Fischer,'64, Siredon; Bolau,'99, A.Tigrinum; Dustin'11, Axolotl and others) the description here is brief. In addition to two series of microscopical slides through the head and neck region of A.punctatum (one just metamorphosed, the other an older adult), several specimens (A.tigrinum, 15cm. and 22cm.long; A.jeffersonianum etc.) were used for gross dissection. Although minor differences occur in the location and appearance of the gland in the individuals, on the whole its relationships is fairly constant. Variability in the gland was noted by Bolau('99) who says, "Ein Constanz im Auftreten der Thymus der Zahl nach habe ich bei Amblystoma tigrinum selber oder bei der weissen Varietät nicht finden können. Die Zahl der Drüsen wechselte nicht nur individuell, sondern ich fand auch Verschiedenheiten bei demselben Thier auf den beiden Seiten." The following description is based upon the gross dissection of A. tigrinum.

The gland is easily exposed (fig.37) by removing the skin from the side of the neck in the region caudal and dorsal to the angle of the jaw. It is generally a light gray, somewhat elongate, flattened, three-lobed structure of considerable size (3-6mm.long, and 0.5-1.5mm. broad), lying in the loose connective tissue just dorsal to the caudal region of the first branchial cartilage, and closely pressed against the deeper lying dorso-laryngeus (d.l.) muscle. (In some cases the surrounding connective tissue is deeply pigmanted, in the region of the gland so that its light color is masked, in others this pigmented area is some distance below, enveloping then the carotid gland and epithelial bodies, which are described elsewhere).

The three lobes, one behind the other, are usually in a line, a little oblique to the longitudinal axis of the body. The anterior lobe (probably the

third thymus body of the larva) is a flattened bean-shaped body (between 1 and 2mm.long, and 0.3mm.broad) lying in the angle between the mandibular-pectoralis (m.p.) and the cephalo-dorsalis (digastric) (di.) muscles, its cephalic tip being partly covered by the caudal margin of the latter. The second lobe (probably the fourth larval body) is almost spherical (about 1.5mm.in diameter), and lies a little dorsal but close behind the first. The posterior lobe (probably the fifth larval body) is a flattened ovoid body and is the largest of the three.

The large blood vessels (figs.36 and 40) in this region--the internal jugular vein, the internal carotid artery and the aortic arches-- are exposed by removing the digastric, mandibular-pectoralis muscles, and reflecting the cartilage and muscles of the hyoid apparatus. The connective tissue in which the gland is embedded is well supplied with blood. A small branch from the second aortic arch and one from the external carotid artery enter the region. (For the details of the vascularization of the thymus gland in Adult Axolotl and a discussion of its histology see Dustin '11).

The region of the gland is innervated by several rami of the glossopharyngeal (IX) and vagus (X) nerves. These emerge from the region just caudad to the ear (can be seen after reflecting the muscles in this region), the gland itself and its surrounding connective tissue being innervated by a small twig from the ramus cutaneus (IX) as Fischer ('64) long ago pointed out in Siredon.

2. Thyreoid.

The anlage of the thyreoid is first recognized in Amblystoma, as in a number of the other amphibians in which its development has been studied, (Triton, Maurer '88; Muthmann '04; Necturus, Miss Platt '96; Hypogeophis, Marcus '08; and Axolotl, Maurer '88; and Muthmann '04) in the late embryo and early larval stages. Muthmann ('04) describes its earliest appearance in embryos of Triton and Axolotl of 21 somites, but carries his study only to the hatching stage, 30 somites (probably about 4mm. long). In the following account the description of it begins with embryos 5mm. long, thus roughly corresponding to the last stage described by Muthmann.

A. Amblystoma larvae, 5mm. long.

At this stage, the general features of the pharyngeal region are not much different from those earlier described in dealing with the thymus bodies. The place where the mouth is to form is easily recognized, being indicated by an extensive oral plate, into which there extends from behind, the now spacious pharyngeal lumen, lined throughout by a comparatively thick layer of yolk-filled entodermal cells. The caudal end of the lumen is continuous with the rest of the primitive alimentary tract, which dips ventrally in the region caudad to the heart to form the anlage of the liver. As yet the pharyngeal pouches are indicated by mere grooves along the sides of the pharyngeal tube, the dorsal wall or roof of the tube being composed of a rather uniform layer of cells. The thyreoid body arises from certain cells lying in the median floor of the pharyngeal tube, in the region between the oral plate and the heart.

In the region of the early anlage of the hyomandibular pouch (not the second branchial, as Maurer '88 described in Triton), and in front of the anterior limits of the pericardial wall, the entoderm in the mid-line of the floor of pharynx thickens and at the same time folds in such a way as to form a very

shallow cup-like depression which protrudes ventrally and a little caudad between the mesodermal cells of the third somite of the head below. This is the early anlage of the thyreoid, and because of its close proximity to the heart region in the earlier developmental stages, was interpreted by Brachet ('98) as a part of the heart, (see Muthmann, '04, fig. 31, which was taken from Brachet's fig. 8, p. 34) his error being later corrected by Muthmann.

The marginal limits of this cup-shapped thyreoid anlage are not well defined. Figure (1), represents a section taken as nearly as possible through the medial sagittal plane of the thyreoid anlage of this stage. On either side of this section, the ventrally directed fold of entoderm is less pronounced. Transversely, the anlage is cut in five successive sections, (10mu each), the general appearance of the anlage is shown in (fig. 2), and somewhat in more detail in (fig. 3). On either side of the anlage, mesodermal cells are forming the mandibular arteries, but there are no other structures yet formed in this region. The approximate lateral limits of the anlage in this stage are indicated by r, r.

From the phylogenetic standpoint much interest attaches to the question as to whether the early anlage of the thyreoid in the amphibia is solid or hollow. In Amblystoma, it is evidently solid, and thus is similar to the structure found in Triton, Siredon, Salamandra by Maurer ('88); Salamandrina by Livini ('02); and Triton by Muthmann ('04). Miss Platt ('96), on the other hand, claims that not all the urodeles have a solid thyreoid bud, but some may have a hollow one, as was the case in Necturus described by her. Marcus ('08), finds a hollow anlage in Hypogeophis, a Gymnophionian. In the anurans, contradictory statements are also found in the literature regarding the primary nature of the anlage. In Bufo and Rana, Maurer ('88) claims it is first vesicular and two days after hatching it becomes solid, but W. Müller ('71), observed a solid one in Rana temporaria and R. platyrrhinus, in which the first lumen appeared in

25mm.larvae, after the gland had divided into two halves.

In Amblystoma, the cells of the solid distal end soon proliferate and form an elongated cylindrical bud in the stage next to be described.

B. Amblystoma larvae, 8mm.long.

Before proceeding to the description of the thyreoid anlage in this stage, certain shiftings due to growth of the surrounding parts may be described. By marked increase in size of the brain and spinal cord above; the forward and upward growth of the pericardial chamber and its contents below; and the lateral growth of the walls of the pharynx to form the pharyngeal pouches; the pharyngeal cavity has been greatly modified, being depressed dorsoventrally. Below, and to the sides of this pharyngeal tube, in the region between the thickened oral plate (the mouth being still closed) and the anterior wall of the pericardial chamber, numerous accumulations of mesodermal cells occur, which have a considerable effect upon the position of the thyreoid anlage in this and subsequent stages. Figure (45) represents a reconstructed portion of the thyreoid anlage in this stage, and shows its relation to the pharyngeal entoderm, and the accumulations of mesodermal cells which are to form the copula and the cartilages of the branchial apparatus.

The thyreoid anlage is now a solid, cylindrical rod of cells (tr., fig.45) of considerable length (about 100mu long) connected anteriorly with the cells of the medial ventral floor of the pharynx. Its distal end extends in a horizontal direction toward the anterior wall of the pericardial chamber, but stops short of the latter by about 40mu. The fact that the thyreoid outgrowth in Amblystoma, does not reach the pericardial wall in this, and in later stages, is a point of difference in its development from that recorded by Miss Platt in Necturus. In describing the thyreoid outgrowth in a 13mm.larva, which from her figure 6 (p.562), corresponds closely to the stage here under discussion,

she says," From the floor of the alimentary canal, the thyreoid outgrowth extends backward as a solid bar of tissue to the anterior wall of the pericardium with which its posterior cells come into intimate contact". This fact she further emphasizes in her conclusions, " it remains in contiguity with the pericardium as long as its union with the floor of the branchial cavity is retained". In none of the developmental stages of Amblystoma have I seen any intimate relation of the thyreoid anlage to the anterior wall of the pericardium.

Figure (4) is a medial sagittal section through the thyreoid anlage (tr.) in this stage. At (st.) the stomodeum, the entoderm touches the ectoderm and forms an oral plate of considerable thickness where later the mouth is to break through. In the space above the thyreoid anlage and between it and the ventral wall of the pharynx is an accumulation of numerous darkly staining mesodermal cells (co.), which form the early anlage of the copula of the branchial arches, while below the anlage or a little to either side of it, close to the ventral surface of the body wall, are the early anlagen of the genio- and mylo-hyoideus muscles. (The last named structures are shown in transverse sections, see fig. 7). This figure is taken in the plane indicated by the line d-d of fig.4.

Figure (6), is through the most caudal lateral extremity of the hyomandibular pouch (taken in the plane indicated by the line c-c of fig.4), and shows not only the thyreoid anlage (tr.) at its point of junction with the pharyngeal entoderm of the middle line of the floor of the pharynx, but also the anlage of the first thymus body as described in another place. The anlage of the geniohyoideus muscle is a mass of illy defined cells at the lateral side of the thyreoid, while the anlage of the mylohyoideus muscle (m.hy.) is somewhat more plainly outlined immediately below it.

Figure (7), is about 75mu caudad to the the one just described (taken in the plane indicated by the line d-d, of fig.4), and shows the thyreoid in this

region completely isolated from the pharynx. A broad sheet of mesodermal cells to form the copula and branchial arches is now interposed between the thyreoid anlage and the pharyngeal floor, while below, is the anlagen of the muscles, which are much the same as in the other section.

In this stage a differentiation in the appearance of the cells of the different germ layers has begun. The cells of the pharyngeal wall and those of the thyreoid outgrowth are still filled with yolk granules and are much lighter in color than those of the mesoderm in which the yolk is rapidly being absorbed. This differentiation is however more pronounced in the stages immediately following. Microscopically, there is little difference between the cells of the pharynx, and those forming the distal region of the thyreoid anlage, both having large round or oval nuclei.

C. Amblystoma larvae, 9.5-11mm. long.

This stage may be characterized as the period of most rapid development, both for the general structures, and for the thyreoid anlage. The mouth is now open except in the 9.5mm. larvae, the gill pouches have fused with the ectoderm, and the slits are open. The ventral mesoderm forms well defined structures- the branchial arches, and blood vessels-in the region below the pharyngeal tube.

The anlage in the 9.5mm. larvae, is slightly longer (about 140mu) than that in the 8mm. larvae, the proximal end is still in intimate with the pharyngeal entoderm, while the distal end is divided into right and left halves. This division however effects as yet only the caudal extremity of the anlage (about 40mu), thus giving to the whole, a Y-shaped appearance, with the forks of the Y much shortened. Figure (13) is a section through the caudal region of the anlage in this stage, the right and left halves lying just dorsal to the geniohyoid muscle. In the region above the thyreoid anlage, the mesodermal cells plainly show the relative positions of the anlagen of the copula (co.) in the medial region, and the hyoid (hy.) and the first branchial arch (c.br.1), the

relations of which will be detailed in 10mm. larvae, below. The inferior jugular vein lies a little lateral to the thyreoid anlage, while the external carotid artery is smaller and is latero-ventral to the jugular.

In the 10mm. larvae, the relationships differ considerably from those just described. The thyreoid anlage has severed its connection with the floor of the pharynx, and in addition is divided completely into right and left halves, which assume a position a little lateral to the geniohyoideus muscle of either side, the cephalic ends of each being about in the plane with the junction of the first branchial arch with the copula. The relative positions of the thyreoid anlage and the developing copula and branchial cartilages in the present and previous stages are the result of differential growth. The thyreoid anlage has separated from the pharyngeal epithelium and is carried backward below the copula, and at the same time it has divided into right and left halves, the keel of undifferentiated tissue extending ventrally from the copula (possibly the anlage of the external rectus muscle of the hyoid or the first branchial cartilages) intervening between the halves. Maurer ('88)p.360, in describing this stage in Triton says, " Dann (two or three days after hatching) beginnt die Differenzirung des knorpeligen Kiemenapparates und die Kiemenspalten öffnen sich. Die Schilddrüsenanlage wird von ihrem Mutterboden weiter entfernt, durch die Copula des Hyoidbogens. Zugleich beginnt sie sich zu theilen, so dass am fünften Tage die beiden Hälften nur durch einen dünnen Isthmus zusammenhangen".

The division of the thyreoid anlage described above leads to the brief consideration of two points; the fate of both the cells which formed the connection between it and the pharynx (the duct of the other glands) and of those which connected the halves before their separation. Miss Platt ('96), in Necturus, found cells from the anterior part of the 'broken outgrowth' (thyreoid) distributed upon the dorsal surface of the mylohyoideus muscle, which were finally lost in the muscular tissue. She also found a few scattered cells from the

anterior part of this outgrowth, above the level of the geniohyoideus muscle, the fate of which she could not follow, but in her material they did not develop into accessory thyreoids.

Maurer ('88) in Triton, on the other hand, found cells in this region persisting for a considerable length of time, which he interpreted as accessory thyreoid. These he thought were originally part of the isthmus, which eventually formed a group of four or six cells containing colloid, lying in the mid-line between the geniohyoideus muscle of either side. He says, p.361, " In Folge dieser raschen Lageveränderung der Schilddrüse, kurz nachdem sich die oft unregelmässige Theilung vollzogen hat, bleiben häufig, besonders weiter vorn in der Medianlinie zwischen den Musculis geniohyoideis, Theile des ursprünglichen Isthmus liegen, welche später als vordere unpaare, aus vier bis sechs Acinis bestehende colloidhaltige Nebenschilddrüsen sich erhalten".

In Amblystoma, I am unable at any stage to locate cells in this region which may be interpreted as an accessory thyreoid. There are to be sure, a few scattered cells, lying in the space between the geniohyoideus muscles and the copula in this region, but these are similar in appearance to the numerous mesenchymatous cells of this same region, and are not sharply differentiated from them. If these scattered cells can be looked upon as the remains of the isthmus of the two halves, it is clear that they are rapidly degenerating, and have lost the staining qualities, which is still retained by those of the thyreoid, and are being dispersed into the surrounding connective tissue in a manner similar to that described by Miss Platt in Necturus, and do not form persisting follicles like those which Maurer interpreted as accessory thyreoid in Triton.

Each half of the thyreoid is now an elongate, ovate, mass of epithelial cells (about 150mu long), lying in the connective tissue, its long axis

paralleling the sternohyoideus muscle of either side, the anterior end of the thyreoid which appears in the same section with the anterior wall of the ear, and the caudal end stopping short of the anterior wall of the pericardial chamber by 60 or 70mu. Although somewhat interrupted and irregular in places, the cells of which the halves are composed, are, for the most part solidly packed as in the earlier stages, and they retain to a considerable degree, the yolky character as do the cells of the pharyngeal wall at this stage. The principal blood vessels of the region (the inferior jugular vein, and the external carotid artery) although faint in outline, are fairly easily recognised, these, and their branches running for the most part through the region lateral, and a little dorsal to the thyreoids of either side. As development proceeds, the cells of each half of the thyreoid pass laterally and dorsally, so that they soon come to lie close to the medial wall of the inferior jugular vein.

D. Amblystoma larvae, 13mm. long.

In the 13mm. stage, the cells of the thyreoid have changed noticeably in their appearance and arrangement. They no longer form solid anlagen, but are more scattered throughout the surrounding connective tissue. For the most part they are free from one another, but are arranged in a broken line on either side of the body, paralleling the inferior jugular vein for a distance of about 300mu. It is difficult to make more than general statements of the arrangement of these cells throughout their extent, since this varies greatly on the two sides of the body. As a rule, the cells have migrated laterally and dorsally, and now are arranged about the wall of the inferior jugular vein, and occupy in places, the spaces between the walls of the jugular and its junction with numerous smaller branches, some even lying in the space between the jugular and the lingual branch of the carotid artery which lies some distance lateral and dorsal to it. In color, and general form and size, these cells are well differentiated from the surrounding mesenchyme on the one hand, and from the pharyngeal cells from which

they have had their origin on the other. These differences in color and shape are interesting, since Miss Platt ('96), in her description of this stage in Necturus remarks that," they are distinguished from the surrounding mesenchyme merely by their closer grouping." Maurer ('88) notes the condition of the thyreoid cells in Triton in this stage in the following terms, (p.362)," So lange die Zellen der Schilddrüse Dotterblättchen enthalten, ist das Organ leicht zu erkennen. Zwei bis drei Wochen nach dem Verlassen des Eies verschwinden die Dotterblättchen und est hält dann eine Zeit lang schwer, die Schilddrüse aufzufinden. Sie besteht jederseits aus einem wenig vortretenden soliden Zellschauch, der an dem bezeichneten Platze, vor dem ersten Arterienbogen, gerade hinter dem zweiten Keratobranchiale, zur Seite des Sternohyoideus liegt."

E. Amblystoma larvae, 15mm. long.

Aside from the continued growth of the surrounding parts, but little change is noted in the relationships of the thyreoid cells from that of the 13mm. stage. Although distributed over practically the same area and the same region of the body (occuring in 19 successive sections, 20mu thickness each, or 380mu total distance along the inferior jugular vein, and extending from the point of junction of the first branchial cartilage with the copula to the region of the anterior wall of the pericardium), the cells have increased in numbers and are more compact; a few, (three to six) in a group, and several groups usually being cut in the same section. This arrangement of the cells in groups is the first indication of the formation of follicles, which are developed rapidly in the stages immediately following this.

Contradictory statements are made as to the exact manner in which the thyreoid follicles are developed from the primary anlage. W. Müller ('71), claimed that the thyreoid gland in all vertebrates passes through three stages: (1) a severing of the anlage from the pharynx; (2) the formation of a network of tubes of glandular epithelium; and (3) the formation of follicles from

these tubes. Stockard ('06),in the Myxinoids (Bdellostoma) and Gudernatsch ('11),in the teleosts have shown that the second stage may be suppressed or absent. In the trout, Maurer ('86) says that the formation of follicles is very simple; solid buds form on the primary vesicle (which is here hollow instead of solid as in the urodeles), central cavities soon form in these,each then separates. L.Muller ('96),believes that new follicles originate in the teleosts,from the older as buds from the epithelium which subsequently become free. Gudernatsch ('11,p.721) says, " The reptiles,birds and mammals are said by the majority of observers to show a vesicular thyreoid anlage,which changes into a compact organ from which follicles later originate. Kölliker, however, observed in the rabbit a thickening in the ventral wall of the pharynx, from which a wart-like solid process was cut off. Born also records the same for the pig."

It would seem,from facts recorded above,that the formation of the follicles in Amblystoma differs slightly from Maurer's account of the urodeles he studied (Triton,Salamandra atra and Siredon), in that the solid cylinder of epithelial cells forming the thyreoid anlage (right and left) breaks up into groups of cells which become scattered loosely about the wall of the blood vessel (the inferior jugular vein),or in the connective tissue of the region,and subsequently these isolated cells increase in number by mitosis and form the walls of the follicles. Although Miss Platt, ('96) in her description of the development of the thyreoid of Necturus does not enter the discussion of this point,it is very evident that she noted a similar condition when she says,"one finds in place of the solid thyreoid outgrowth (17-18mm. larvae),two lines of cells extending obliquely outwards-----,forming neither a solid mass,nor walls of closed vesicles (follicles). These cells of the thyreoid migrate dorsalwards ------- distinguished in an embryo of 19mm. as a group of cells lying on each side,between the lateral surface of the sternohyoideus------ . In an

embryo 21mm., one or two small vesicles (follicles) are found where the group of cells (th.) lie in fig.8. These vesicles increase in number as the embryo grows until in a little amphibian of 46mm., they constitute a considerable mass of vesicular tissue".

The relative position of these cell groups (which we may now call follicles) differ not only in individuals, but on the two sides of the body in the same individual, so that only a general description need be given here. The most anterior group on the left side is cut in the same section with the anterior wall of the ear. It consists of six to eight cells lying close against the dorsal wall of the inferior jugular vein, a small group on the right side (the most anterior of this side) occur some distance back of this (about 60mu), the cells of which are pressed against the latero-ventral surface of the sternohyoideus muscle of this region. From this point caudad for 350-80 mu on either side, various other thyreoid follicles occur, the exact details of the positions of which may be omitted here.

These developing follicles in this stage are also variable in form. Some are globular or elliptical, with a well defined margin of outer cells and have a lumen, while others are very irregular in outline, and are solid masses of cells with no cavity. The first of these types usually occur as isolated follicles, lying singly in the supporting tissue, while the others occur in regions of greater conjestion and crowding. So far as I am able to say, there is no enveloping membrane (membrana propria) in this stage, either surrounding the individual follicles, or enveloping collectively the follicles to form the gland.

F. Amblystoma larvae, 19mm. long.

In the 19mm. stage, and all subseguent larval stages studied, the thyreoid follicles are so massed as to form a well defined structure on either side of the body, the definitive thyreoid gland, which changes but slightly in its

position. The follicles here, as in the 15mm. larvae are irregular in size, form and relative distribution about the wall of the inferior jugular vein of either side, and extend in a longitudinal direction a little more than 400mu on each side. As before, the most anterior follicles are cut in section with the anterior wall of the ear, the most caudal occur some distance (about 80mu) in front of the anterior wall of the pericardium. Typically, the follicles in this stage are relatively small spherical or slightly ovate bodies, varying between 19 and 36 microns in major diameter, and showing in section, a layer of cuboidal cells about the outer margin, enclosing a conspicuous cavity, which in all probability contains a fluid of some sort, but which as yet, does not have the staining properties of colloid. In some cases a slight marginal membrane about the layer of cuboidal cells is noticeable, in others apparently there is none.

The follicles are more numerous throughout the central region of the gland, on either side than at either extremity, and they are separated from each other by conspicuous spaces (large or small in comparison to the individual follicles of the region) in the connective tissue in which they are embedded. These spaces for the most part are lymph vessels, although here and there, there are small veins (especially those returning blood from the geniohyoideus and sternohyoideus muscles), which unite with the inferior jugular vein in this region as already pointed out above. This complex of follicles, lymph spaces, blood vessels and loose cells and strands of connective tissue, is maintained in the central portion of the gland, but at the two extremities, these relations are not so conspicuous.

So far as I have observed, there is no good evidence that either the inferior jugular vein, or the smaller twigs from the muscles break up into a 'rete mirabile' in this region, a fact which, when taken in connection with facts to be brought out in later larval stages is of considerable interest, and con-

cerning which more will be said below. Aside from this general treatment, no attempt is made here to describe the histological relationships of the parts in the thyreoid gland.

The thyreoid gland changes but little in the succeeding larval stages, and hence but little space need be given to it.

G. Amblystoma larvae, 26mm. long.

In the 26mm. larvae, the gland is distributed along the inferior jugular vein for a distance of 350 or 400 microns; that on the right side occuring in 35, and that on the left, 40 successive sections (10mu each). A few isolated follicles lie in the same section with the anterior wall of the ear, and on the right side these lie some distance medial to the inferior jugular vein. There is no regularity in the arrangement of these follicles on either side. Most follicles have conspicuous lumina, but as yet these contain no colloid. The lymph spaces are somewhat larger and more prominent, but otherwise there are no great differences from the 19mm. stage.

H. Amblystoma larvae, 35mm. long.

The thyreoid in the 35mm. larva has elongated, now being between 450 and 500 microns in length on either side, the anterior end occuring in sections with the anterior wall of the ear, the caudal region extending to within 60 or 75 microns of the anterior wall of the pericardium. In addition to this increase in length, the gland is now enveloped in a very thin connective tissue sheath, which surrounds, not only the follicles and lymph and vascular spaces, but also includes the large trunk of the inferior jugular vein for a considerable distance in its course through this region. The inferior jugular vein enters this sheath, but in this and later stages, it does not break up into a 'rete mirabile'. The external carotid artery, which courses lateral to the gland, is not enveloped in the connective tissue sheath of the gland and has no intimate connection with

the thyreoid in this stage. The lumina of the follicles are now larger in comparison than before, but as yet there is no colloid.

I. Amblystoma larvae, 39mm. long.

In the 39mm. larva, the thyreoid gland is a well defined ovate, somewhat flattened body, a little less than a millimeter long (between 750 and 800mu), lying dorso-medial to the inferior jugular vein on either side of the body. The connective tissue envelope is here more pronounced, and a few of the follicles contain colloid. Figure (47) is a wax reconstruction of the gland and the cartilages of the branchial apparatus in this stage. The follicles are rather large throughout, and are more numerous in the central and caudal region.

J. Amblystoma larvae, 45mm. long.

In the 45mm. stage (the last to be described before transformation), the gland is about a millimeter long, occuring in 51 successive sections (20 mu each). Nearly all of the follicles are now filled with colloid. In a section through the central region of the gland, (fig. 31), eleven follicles (fol.) are cut, these almost completely surround the inferior jugular vein, which in this region is within the connective tissue sheath. The follicles are separated from one another by vascular and lymph spaces (v.v.). Nearly all the follicles in this section show an outter lining of cuboidal cells with spacious lumina within.

K. Transforming Amblystomae.

In the early stages of transformation, the gland is noticeably shorter, and with the greatly increased size of the surrounding muscles (genio- and sterno-hyoideus, and adductors) it has a more lateral and ventral position close to the ventral wall of the body. It is now between 800 and 900mu long, this reduction continuing in the two succeeding stages, to between 712-775mu and 550-660mu respectively. To compensate for this shortening, the follicles are crowded to-

gether, those at either extremity having apparently been pushed into the central portion by the growth of the surrounding parts, the result being that the central portion of the gland is now greatly enlarged and elliptical, in section measuring between 475-625mu in major, and between 225-390mu, in the minor diameter of the ellipse.

The following description is based upon a wax reconstruction of the gland in this stage, (fig.43). The follicles are few (fourteen or fifteen in all) but have increased in size; some being now about 100mu long, and between 50 and 75mu in diameter. The anterior extremity of the gland consists of a single large follicle, which lies dorsal to the wall of the inferior jugular vein, and which like all the others, is full of colloid. Just behind and a little lateral to this, is a second follicle of about the same size, similarly placed upon the wall of the jugular. Following these, numerous other follicles are irregularly arranged about the vein, so that in the caudal region of the gland, the vein is completely surrounded by them. The spaces between the follicles are occupied by small blood vessels and the lymph sacs.

Later, when the distal ends of the second, third and fourth branchial arches are greatly reduced in length, and as a consequence, the corresponding pharyngeal clefts are greatly modified (the third and fourth closed, and represented by short lateral processes of entoderm; the second still open but reduced); these changes, although not affecting directly the thyreoid, modify the hypoglossal and the hypobranchial musculature and blood vessels, which, in turn, have a direct effect upon this structure. The gland on either side is short and ovate, measuring in the long axis of the body 712mu, on the right, and 775mu, on the left, and in section in its central region varying from 390 to 510mu in diameter. It lies, as before in the reduced space between the now much enalrged sterno- and mylo-hyoideus and adductor muscles, and is close upon the wall of the inferior jugular vein. The gland appears in the same section with the anterior wall of

the ear, but the anterior wall of the pericardium is about 250mu caudad to its posterior end. This relationship is interesting, since in the next stage there is a difference in the relative position of the heart and the gland.

When transformation has proceeded so far that the arrangement of the hypoglossal muscles, branchial arches, blood vessels and other parts is practically that of the adult, only the hyoid and the first and second branchial arches remain, the latter (second arch) is much reduced in size and length; the gill-slits are completely closed, only mere rudiments of pharyngeal entoderm marking their former position. Simultaneously with this rearrangement, the thyreoid gland of either side has been converted into a compact, egg-shaped mass of follicles, and has migrated laterally and a little caudally, so that it now lies lateral to, and a little in front of the pericardial chamber, in the space just back of the caudal tip of the second branchial cartilage, between the adductor muscle of the first branchial cartilage, and the large medial sternohyoideus muscle. The position of the gland to the cartilages and blood vessels is shown in (fig.46).

The follicles of the gland show great variability in size and shape, and in the color of the colloidal contents, some follicles being light gray, others of brownish or yellowish hue. The differences in the number and size of follicles and the variety in their histological appearance, when compared to those of the later larval stages, and those of the adult, would indicate that the gland itself is undergoing a metamorphosis of some sort. Although it is not the purpose to enter here a discussion of the histology of the gland, it is very evident that the larger follicles are giving rise to smaller ones by budding, and that this process of follicular formation, started here in the late transforming stage, continues in the adult. Different opinions have been expressed as to the method of formation of follicles throughout the vertebrates (see Baber, '76; Anderson, '94; Forsyth, '08; and Gudernatsch, 11).

L. Adult Amblystoma.

Tho relations of tho thyreoid gland to tho structuros in tho neck region of sevoral adult urodeles,has been described by a number of investigators (Mauror, '88; Bolau,'99; Drüner,'04; and others) but little is said concerning the morphology of the gland in Amblystoma. Maurer, after describing the development of the gland in Triton remarks,(p.363) " bei Siredon pisciformis findet die Anlage der Schilddrüse-----in der gleichem Weise bei Triton taeniatus statt", but he says nothing concerning the later larval and adult stages. Although,in the main,the facts of development accord with Maurer's description of both Triton and Siredon,Amblystoma differs in one or two points from either. I therefore give here a brief description of the gland,based for the most part upon the gross dissection of the gland in several adult Amblystomae,chiefly A. tigrinum.

By removing the skin and caudal portion of the mylohyoideus muscle of the ventral surface of the neck the gland is seen (tr.,fig.36) embedded in rather loose connective tissue,in front and a little lateral to the pericardium,flanked medially by the genihyoideus,laterally by the hyoideus internus of the first branchial arch,and dorsally by the deeper lying sternohyoideus muscles. It is a rather flattened ovate body (between two and three millimeters long ,and from one to two and a half millimeters broad),differing in shape and size in individuals, and on either side of the same individual. It is gray or yellowish or even sometimes brownish in color. Usually the cephalic end is pointed and the caudal blunt. Although somewhat variable in their relation to the gland,the blood vessels are very conspicuous. The inferior jugular vein is now large and prominent,and passes lateral to the gland as it courses toward the heart; the external carotid artery parallels it closely as it passes forward from the carotid gland.

The gland and blood vessels were removed from several individuals and were

cleared and mounted. Four glands were thus treated; both right and left glands of A.tigrinum 15cm. long, and one gland each from other specimens of the same species, 17.5 cm. and 22 cm. respectively. The blood supply of the gland is variable. In most cases, the interfollicular net-work of the gland is formed by the small venous twig which passes caudad from the lateral surface of the geniohyoideus muscle which enters the anterior medial region of the gland, and emerges from its posterior medial surface to join the large trunk of the jugular vein some distance caudad. In one instance the venous connection of the gland with the jugular vein is made by a small twig coming from the sternohyoideus muscle. In none of the preparations does the large jugular trunk itself break up to form the complex 'rete mirabile' which has been described by Maurer in Triton alpistris (see his figure 22, a and b).

The gland is rarely connected with the carotid artery. In only one case could I trace a small thyreoid artery into the vascular net-work of the gland. Such a condition in Amblystoma accords with Maurer's description in Triton. In the live Triton, he showed that the circulation of the blood continued in the gland when, with forceps, he closed the carotid artery just caudad to the gland. On the other hand, he was able to bring the circulation to a standstill when he closed the twig of the jugular vein in front before it entered the gland. He therefore concludes, "dass die Schilddrüse der Tritonen in den venösen Kreislauf eingeschaltet ist, eine Thatsache, die ich nirgends erwähnt finde und welche wohl auch für die Schilddrüse einzig dasteht. Von mechanischem Wert für die Blutcirkulation des Kopfes kann dieses Verhalten nicht sein, weil sehr häufig nur ein Ast der Jugularvene diese Wundernetzbildung zeigt. Auch die Ernährung der Schilddrüse leidet nicht darunter, da aus vielen Hautkapillaren Blut, welches somit die Hautathmung durchgemacht hat, in den Stamm der äusseren Jugularvene übergeht und somit der Sauerstoffgehalt immer noch ein genügender ist, zumal ja auch das Arterienblut hier ein gemischtes ist".

It is also probable that it is not necessary that the thyreoid in Amblystoma be connected with the carotid artery in order to carry on its metabolic processes, since the blood in the jugular twig, returning from the capillaries of the skin contain sufficient oxygen for the functioning of the gland.

3. Postbranchial body.

In its development and morphological position, the postbranchial body in Amblystoma is 'postbranchial' in the sense Maurer used the term in (Triton, Siredon and Salamandra), and not 'suprapericardial' (van Bemmelen) as Miss Platt found in her study of Necturus. The body is caudal to the last gill-pouch (fifth visceral or fourth branchial) in about the position where one would expect to find a sixth visceral pouch (fifth branchial), and not cephalad to the posterior pouch as in Necturus. As a rule, the body in Amblystoma is asymmetrical in its development, usually occuring on the left side (in this respect agrees with Triton and Salamandra) but in one individual (19mm. larva, see below) it appears on the right side as well, and in this stage more closely agrees with the conditions described for Necturus (Miss Platt '96) and Hypogeophis (Marcus '08), although the body on the right is smaller, and possibly persists but a short time.

A. Amblystoma larvae, 8mm. long.

The earliest stage in which the anlage of the body is recognized with certainty in my material is in larvae 8mm. long. Maurer was able to distinguish it earlier in Triton, even in an embryo before hatching (see his account, p. 362). 'Bei Tritonlarven, die eben ausgeschlüpft sind, zwanzig Tage im Ei waren,' etc., but Miss Platt, begins her description of it in Necturus, with a much later stage, (15mm.). Since the region of the body where the anlage occurs has been described in some detail in the discussion of the thymus, it is only necessary to say here that the first appearance of the postbranchial body is in sections which pass through the ganglion of the vagus. Here, on the left side, a portion of the ventral floor of the pharynx, between the anlage of the fourth branchial pouch (fifth visceral), and the anlage of the glottis, becomes slightly thickened. The exact extent of this thickening--both laterally and anterio-posteriorly--at this

stage is impossible to define, as it fades out on all sides, but cells in its central region begin to extend ventrally into the connective tissue above the pericardial wall there to form the anlage of the postbranchial body. Figure (10a) is through the thickened portion where the ventral cells forming the postbranchial anlage is most pronounced. The lateral limits of this anlage are marked roughly at points, r-r, medial to which is the anlage of the glottis, and lateral to which is the anlage of the fourth branchial pouch, while four or five large procartilage cells below them mark the position of the anlage of the fourth branchial arch. At this time there is no other noticeable differentiation between cells of the pharynx and those of the postbranchial anlage, both containing a considerable amount of yolk.

B. Amblystoma larvae, 9.5mm. long.

In this stage there is considerable advance in the development of the postbranchial body. By proliferation, cells have been pushed in a ventral direction from the thickened anlage, so that they now form a well defined, short-stalked cylindrical body, protruding vertically downward toward the dorsal wall of the pericardium. This anlage is about 40mu long, and between 25 and 30mu in diameter. The cells of the anlage are closely packed; the body is solid; and as yet no histological differentiation is apparent. (That this early anlage is solid in Amblystoma, and remains so for a considerable length of time after the pharyngeal pouches have opened to the exterior, would seem to be a point (though not conclusive) in favor of Maurer's interpretation of it as a 'postbranchial' structure, and not a rudimentary sixth pouch, a view which Greil ('05) opposes. On the other hand, this solid structure in Amblystoma is quite different from the early anlagen of the bodies described by Miss Platt in Necturus, where she finds them--one on either side--forming "small vesicles immediately below the floor of the branchial chamber, with which they are still connected by stems----. They are formed by a single layer of yolk-laden cells whose nuclei are near

the surface of the vesicle, while the yolk granules are aggregated at the centre". Figure (15) is a transverse section through the postbranchial anlage (pb.) at this stage, and shows its relation to the surrounding structures. This section is just caudal to the posterior wall of the ear, and cuts the glossopharyngeal and vagus ganglia, as well as the internal jugular vein and the first and second efferent branchial arteries. It also shows the lateral extensions of the successive pharyngeal pouches (third, fourth and fifth visceral) which extend to varying distances toward the ectoderm of the lateral surface of the body, and between which occur the anlagen of the branchial cartilages.

C. Amblystoma larvae, 10-11mm. long.

In the 10mm. larvae, there is but little advance over that of the 9.5mm. The anlage has lengthened (is now about 60mu long) and reaches nearly to the dorsal wall of the pericardium, and at the same time it is reduced in its minor diameter (now between 15 and 20mu) so that in appearance, it is a solid finger-shaped spur of entodermal cells, reaching from its point of contact with the pharynx toward the pericardial chamber. This finger-shaped anlage (pb.) is shown in fig. 20. As yet it has no lumen, and its cells show no marked histological differentiation from those of the pharyngeal wall.

In the 11mm. larvae, although still in connection with the pharyngeal wall, the axis of the anlage is changed noticeably, the distal end now turning medially and caudally, so that in five successive sections, only the first and second show the connecting stalk, the remaining three pass through the distal portion of the anlage, which now lies almost parallel to the long axis of the body. The cells of the anlage have changed somewhat in their histological appearance, especially in their distal region, where they are much darker in color (due probably to the loss of yolk), and where the tissue is less compact. A few cells in this region have separated from the others and lie scattered in the connective tissue; some lying close to the medial wall of a small twig from the fourth

branchial artery, and others some distance from it.

D. Amblystoma larvae, 13-15mm. long.

The postbranchial anlage has now taken a position parallel to the long axis of the body, this change in position being due probably to the increase in size of the surrounding parts. The connection with the pharynx is lost and the body now lies completely isolated--an elongate, irregular, illy defined mass of cells in the connective tissue, between the medial aditus laryngeus muscle and the more lateral cartilage anlage of the fourth branchial arch, and the dorsal wall of the pericardium. A few scattered cells in its anterior region persists as a remnant of the connecting stalk; these extend upward toward the ventral floor of the pharynx, while cells in its caudal region are scattered in the connective tissue and are poorly defined. The central region is solid and is nearly 50mu long and about 10mu in average diameter, although in places it is very irregular as already noted. This stage corresponds roughly to that described by Maurer in Triton (p.362), "Schon vier Tage später hat sich dieser epitheliale Zellzapfen von der Schlundwand abgeschnürt und liegt als solide Zellkugel direkt unter der Schlundwand, seitlich vom Kehlkopfeingang".

E. Amblystoma larvae, 19-20mm. long.

In a single specimen, 19mm. long contrary to the usual condition, two postbranchial structures are developed, one on the right, and the other on the left side of the body. Both have the same general structure, and occur in the same relative position on the two sides, being cut in the same transverse sections, although the right is much smaller. The right body is about 105mu long, and about 20mu in average diameter, while the structure on the left is 165mu long, and nearly 50mu in average diameter. A transverse section through the central portion of the body on the left side is shown in fig.(25). Both, for the most part, are compact but here and there throughout their extent each shows the presence of small

cavities, which have the appearance of lumina, but which do not contain colloid. These cavities, are not continuous with one another; they may appear in one section and in the next disappear.

A wax reconstruction of the postbranchial body of the right side is represented in fig.38, and shows that the cephalic end is bent ventrally, so that it lies close to the dorsal wall of the pericardium, and is insinuated between the lateral surface of the aditus laryngeus muscle, and the fourth afferent branchial artery, while the caudal extremity is turned slightly in the opposite direction and lies close to the ventral wall of the pharynx. In addition to a small twig of the fourth afferent branchial artery, which, as mentioned above passes to the ventral wall of the pharynx in this region, numerous lymph spaces now occur, which in places nearly envelop the postbranchial body, especially in the region of its caudal extremity.

Except for the appearance of the body on the right side, as noted above in a single individual, the general position and structure of this body in Amblystoma, at this stage of development, is similar to that recorded by Maurer in Triton, p.362, "In den nächsten (second) Wochen wächst dies Gebilde in Länge, behält seine Lagerung bei und liegt medial von der Knorpelspange des vierten Kiemenbogens. Sehr früh tritt schon ein feines centrales Lumen darin auf; indess macht bei älteren Larven, von 2-3cm. Länge, das Organ noch den Eindruck eines soliden Epithelschlauches und erst nach Metamorphose bildet sich ein weites Lumen, das jedoch niemals Colloid enthält".

The appearance of a postbranchial body on the right side as well as on the left in this specimen, is unusual, since in none of the other stages or specimens is it present. The fact however, is of interest to record, for it indicates, that the development of this body may vary within a single genus of urodeles, as well as among different families, as has been pointed out by Miss Platt.

F. Amblystoma larvae, 26mm. long.

In the 26mm. stage, the postbranchial body on the left side is a fairly compact structure, little different in position and general appearance from that of the 19mm. larva, but in the subsequent stages, several irregularities may occur. In a wax reconstruction, (fig. 44) it is an irregular, elongate body, rather tapered at the anterior end, and somewhat blunt caudally. On its surface, here and there are numerous lobules, resembling follicles but which are unevenly destributed. In section, the cephalic end lies close above the dorsal wall of the pericardium between the aditus laryngeus muscle and the cartilage of the fourth branchial arch, and the caudal end is just below the ventral wall of the pharynx. It extends through fifteen successive sections (10mu each), thus having a length of about 150mu, and for the most part it is solid, only here and there do the sections show a lumen.

G. Amblystoma larvae, 35-40mm. long.

In larvae 35mm. long, the body has divided into numerous smaller components which are distributed over a little greater longitudinal area. Portions of it occur in 18 sections (10mu thickness each), so that it is about 180mu long. The anterior portion (50-60mu long) which appears in the same section with the posterior wall of the ear, is follicular, a layer of cuboidal epithelial cells enclosing a fairly large lumen. Behind this is another portion (40-60mu long), which is oval in shape and solid and is somewhat flattened dorso-ventrally, with irregular bud-like groups of cells on its surface. The caudal end has separated into several cell groups, with large lymph spaces and connective tissue between them. The caudal extremity, as before, lies just below the floor of the pharynx, and the cephalic end close to the dorsal wall of the pericardium.

Drüner's description of the body in 36mm. stage of Siredon (p. 508) differs in several points from that of Amblystoma, especially in being still in contact

with the pharyngeal epithelium. I quote very briefly as follows, " Der Supra-pericardialkörper---------- bestand in der einen aus einer kleinen, ampullen-förmigen Einsenkung des Pharynxepithels, etwas medial von der Stelle, wo die vordersten Bündel des M. interbranchialis 4 am linken Ceratobranchiale 4 entspringen. Diese kleine Ampulle zeigte das gleiche Epithel wie die Pharynxwand, auch Schleimzellen wiesen sich an ihr durch die Färbung aus. Von hier aus setzte sich ein aus kleinen Zellen bestehender Epithelstrang, welcher streckenweise ein feines Lumen zeigte, in ventraler Richtung fort und erstreckte sich so in den von Bindegewebe erfüllten Raum zwischen Herzbeutel und dem genannten Muskel. Hier löste er sich in zahlreiche kleinere Zellenstränge auf, welche mit Unterbrechungen ----verfolgen waren. Hier bildeten sie dorsal von der Wurzel der 3 Kiemenarterie einen grössern Zellenhaufen". In another series of sections however, Drüner was unable to find any trace of the ampulla structure in connection with the pharynx.

H. Late larval and early transforming stages.

Although several stages (40, 45mm. and early transforming) were studied, the postbranchial body changes but little in its morphological relations in any of them. A wax reconstruction of the body in a 40mm. larva, shows it to be a fairly compact structure, somewhat flattened dorso-ventrally, and very irregular in outline (its total length is now about 300mu). As in the early larval stages, the cephalic end insinuates itself between the lateral margin of the aditus laryngeus muscle and the fourth afferent branchial artery, the caudal end taking a more dorsal position. Internally it contains several poorly defined intercommunicating cavities, which run for the most part in a longitudinal direction.

The body in the early transforming stage, although not changed in position, is pressed closely against the medial wall of the fourth branchial arch, by the growth of the now much enlarged aditus laryngeus muscle. This flattens the body laterally so that the lumina are obliterated throughout the greater part of its

length. At this stage the body is about 400mu long, and as in the previous stages, its anterior end is close to the wall of the pericardium, its caudal end close to the floor of the pharynx.

I. Late transforming stage.

In this stage, the parts in the immediate region of the postbranchial body, as well as the general gill region, have changed considerably. The cartilages of the third and fourth arches have now disapeared except for a small medial portion (basibranchial), and with this modification, the blood vessels of the corresponding gills have been affected. By a flattening of the ventral surface of the body of the larva, all structures included in the space between the ventral floor of the pharynx, and the ventral wall, present a much crowded appearance. As a result of this, the postbranchial body is now forced into a very limited space lateral to the aditus laryngeus muscle and between the ventral wall of the pharynx and the lateral strands of the sternohyoideus muscle of the left side of the pericardial wall, where it is reduced to a mass of poorly defined epithelial cells, which contrary to the usual statements for the other urodeles contains no conspicuous lumen. This solid mass of epithelial cells is much reduced in length (now about 90mu long), appearing in three sections, 30mu in thickness each.

J. The adult postbranchial body.

The position and anatomical condition in the adult is somewhat variable. The body is rather inconspicuous and it is practically impossible to recognize it in gross dissection. In transverse sections through the adult head, it is not greatly different from that of the late transforming animal, being a fairly compace oval structure, somewhat irregular in outline, composed of quite large cuboidal cells with a spacious lumen. In position it is somewhat more lateral to the larynx, and the aditus laryngeus muscle, and lies just caudal to the

second aortic arch as it turns dorsally to join the dorsal aorta on the left side. I am not able to lacate the structure with certainty, in sections of an older head. Whether this be due to the fact that the body has degenerated and disappeared, or whether it has (as is claimed for the body in some forms) become closely associated with the thyreoid (lateral thyreoid) I am not able to say, although I incline to the first of these views.

4. Carotid gland and Epithelial bodies.

Although there is no evidence that the carotid gland in Amblystoma arises from cells derived from the entodermal lining of the pharyngeal tube, its appearance in the larva at the time of metamorphosis, and its close relationships to the epithelial bodies in their development, leads to its consideration here.

Different views are held regarding the origin of this gland in the anurans and the urodeles. Maurer ('88), described its development in anurans from the first branchial pouch, and was inclined to believe it had a similar origin in the urodeles. Zimmermann ('98), on the other hand, considered it simply as an enlargement of the walls of the blood vessel in anurans, and Boas ('83) earlier suggested this was the case in Salamandra. Maurer ('02) (p.152) says, "Dies Organ ist hier anzuschliessen. Nach der Auffassung vieler Authoren ist sie eine blosse Gefässbildung, durch Wucherung der Gefässwandung enstanden. Da Andere aber eine Beteiligung von Schlundspaltenepithel angaben, so ist sie hier zu erwähnen. Bei Anuren fand ich im Bereich der 2. Schlundspalte eine epitheliale Knospe, die sich genau so verhält wie die Epithelkörperchen der 3. und 4. Spalte, aber eben durch ihre sehr bald erkennbare Beziehung zur Kiemenarterie sich eigenartig erweist. Nach Zimmermann ist eine Epithelknospe nicht vorhanden, und nur eine Wucherung der Gefässwand bildet die Drüse. Bei Anuren tritt das Organ schon früh bei der Larve auf, während es bei Urodelen erst zur Zeit der Metamorphose sich entwickelt".

In Amblystoma the carotid gland and the two epithelial bodies begin their development during the period of metamorphosis. The Carotid gland is the first to appear, the anlage of this forming on either side, in the region where the first afferent branchial artery enters the gill. The anlagen of the two epithelial bodies of either side appear at first some distance caudad and medial to one another and to the carotid gland; but as development proceeds they are

brought closer and closer together so that in late transforming and adult stages, one lies posterior to the other.

A. Transforming Amblystoma larvae.

In the early transforming stage, the caudal extremities of the pharyngeal pouches are being reduced, the fourth and fifth slits being completely closed to the exterior. The carotid gland is just beginning as a slight enlargement of the wall of the first afferent branchial artery in the region where it enters the first gill-arch, this enlarged portion being augmented by the union of the external carotid artery in front, and the internal carotid artery close behind. At the same time there is a noticeable thickening of the walls of the enlarged portion (anlage of the gland), the origin of the cells of which is difficult to determine. The exact extent of the anlage is difficult to determine, but it is about 150mu long, being cut in five successive sections (each 30mu). Just caudad and somewhat medial, the ventral portion of the second branchial pouch extends downward, separating the first and second branchial cartilages from each other. A similar ventral portion of the first branchial pouch, separates the hyoid and first branchial arches.

The anlage of the first epithelial body in this stage (e.b.$_1$, fig. 39), is an irregular longitudinal tract of entodermal cells, of considerable length (a remnant of the ventral portion of the third branchial pouch), lying between the cartilages of the second and third arches. The cephalic end of this sheet is about 700mu caudad to the carotid anlage, and lies just back of the point where the second afferent branchial artery enters the second gill-arch. The caudal limit is difficult to determine.

The anlage of the second epithelial body (e.b.$_2$, fig. 39), is a similar tract of entodermal cells lying between the cartilages of the third and fourth arches, the cephalic end of which lies just caudad to the point where the third

afferent branchial artery enters the third gill- arch. The cephalic end of this anlage is 360mu caudad to the cephalic end of the first, but the anlagen of both bodies parallel one another, so that in transverse section the cephalic end of the second is cut with the caudal end of the first.

Maurer ('88)in describing these structures in Triton, was unable to find any trace of the carotid gland in the early stage of metamorphosis, he says, p.367, "Ich hatte einige Exemplare von Triton taeniatus, die gerade in der Metamorphose begriffen waren, zur Verfügung. Bei diesen konnte ich keine Spur einer Carotidendrüse nachweisen." He describes however, the anlagen of the epithelial bodies. "Auf Querschnitten zeigte sich zwischen dem zweiten und dritten, so wie zwischen dem dritten und vierten noch vorhandenen knorpeligen Kiemenbogen die Reste der vierten und fünften Kiemenspalten in Form unregelmässiger länglicher Gebilde, die sich aus Epithelzellen zusammensetzen und nur durch Aneinanderlagerung und Schrumpfung der Kiemenplatten entstanden sein können". It is possible that the Amblystoma larva of this stage in my material is somewhat farther advanced in its metamorphosis than was that of Triton described by Maurer.

In the late transforming larvae the gill region has been modified so far that it is similar in many respects to the adult condition. The cartilages of the arches are altered to the hyoid apparatus of the adult; the afferent and efferent branchial arteries now form functional aortic arches; the muscles of the ventral pharyngeal region are greatly enlarged, and as a result, the carotid gland and epithelial bodies are carried somewhat caudal and lateral.

The carotid gland is now an enlarged, ovate body (489x 200mu) situated close behind and a little lateral (about 90 or 100mu from) to the caudal end of the thyreoid gland. It is enveloped in a rather heavy connective tissue covering. The first afferent branchial artery enters it medially, a little toward the caudal end, while the two carotid arteries leave it anteriorly.

The first epithelial body is a well defined oval structure (180x 100 mu),

composed of closely packed epithelial cells surrounded by a conspicuous connective tissue covering, situated close behind (about 150mu) and a little dorsal to the carotid gland, and just lateral and caudal to the second aortic arch.

The second epithelial body is similar to, but somewhat smaller (120x70mu) than the first, and lies close behind (between 60-70mu) and a little lateral to it. The third (very small) aortic arch, passes from the ventral aorta, just in front of the epithelial body, (the epithelial bodies appear in section with the third and fourth thymus bodies, and they lie some distance below them).

B. Carotid gland and Epithelial bodies of Adult.

These structures present only minor differences from the other stages. In a wax model of the parts, (fig.42) on the left side, just after metamorphosis, the carotid gland (c.g.) and epithelial bodies (e.b.) lie close behind one another, embedded in the connective tissue medial to the first branchial cartilage. The first aortic arch (1) passes slightly caudo-laterally, as it leaves the ventral aorta, and enters the carotid gland (c.g.), as before. The second aortic arch (2) is large, and after taking a latero-caudal direction, turns dorsal and cephalad to join the dorsal aorta. The third aortic arch has now disappeared, while the fourth (4) is modified to function as the pulmonary artery (p.a.), a small ductus arteriosus persisting. With these changes in position and function of the blood vessels, the two epithelial bodies are not as closely associated with them, but are more lateral and somewhat more caudal in position. In transverse section at this stage, (fig.35) the epithelial body ($e.b._2$) lies just lateral to the point where the second aortic arch bends dorsally to join the dorsal aorta and is a little below the level of the branchial cartilage (1).

The structures are exposed by gross dissection in fully adult animals (e.b.$_{1,2}$, fig.40), by removing the skin and superficial muscles (see the account of the adult thymus body) from the neck region. They lie in the connective tissue medial to the distal tip of the first branchial cartilage. The carotid gland (c.g.) is a very evident oval body of small size, into which the first afferent branchial artery enters, and from which the external and internal carotid arteries pass forward. Close behind and a little lateral to it, are the two small, whitish, or yellowish white epithelial bodies. These are slightly oval, nearly equal in size (varying from 200 to 300mu in diameter); they lie one closely behind the other and are enveloped in connective tissue which contains considerable pigment. By carefully dissecting out and clearing the parts, it is evident that the blood supply of this region is by two small arteries, one passing back from the second aortic arch, and the other from the external carotid artery. I was unable to trace the origin of numerous small nerve twigs, but it is probable that the region is innervated by branches (probably the third and fourth) of the vagus (X) nerve.

There is little histological difference between the adult epithelial body and that of the late transforming stage. The epithelial cells are solidly packed, separated only by a very fine matrix, the whole surrounded by a well marked layer of connective tissue. Such a compact condition differs slightly from the structure of the body in Triton and Salamandra where (Maurer) they were composed of irregular masses of epithelial cells separated one from another by strands of connective tissue. " Sie bestehen aus unregelmässigen Gruppen von Epithelzellen, welche durch Züge von Bindegewebe von einander getrennt sind".

III. Review of the Literature especially concerning the Amphibians.

A considerable literature deals with the structures derived from the pharyngeal-wall and gill-pouches of the amphibians, and, since various authors have described identical structures in the same species and homologous ones in related formes under different names, the results are sometimes confusing.

Thyreoid.

Although the general anatomy and position of the thyreoid gland in certain adult amphibians was noted by a few workers in the latter half of the last century, notably--Leydig ('53) in Triton punctatus, Landsalamander, Proteus, Caecilia annulata, Rana and Bufo, and Wiedersheim ('79) in Caecilia, Siphonops and Epicrium, and later ('84) the same author noted its position in representatives of both anura and urodelia--the first investigator to describe it from the developmental side was W. Müller ('71) who followed its ontogeny in Rana temporaria and R. platyrhinus. Soon after this, Göette ('75) described its development in Bombinator igneus, and a little later, de Meuron ('86), worked it out in both Rana and Bufo. According to Maurer ('88), no work had been done on the development of the thyreoid gland in the urodeles before he wrote, and what was known of it, was learned from macroscopic study of the adult animal. As a basis of his study, he used series of Triton taeniatus, T. alpestris and T. cristatus (stages in metamorphosis excepted), supplemented by series of Salamandra maculata and young and old Axolotls. He also studied representatives of the anurans--Rana esculenta and temporaria; Bufo vulgaris and variabilis; Hyla viridis and Bombinator igneus. His results are briefly as follows:-

In Triton taeniatus the thyreoid anlage appears before the gill-pouches have united with the ectoderm, as a solid epithelial process, extending ventrally from the floor of the pharynx, between the second gill-pouch and the pericardial cavity. During the first day after hatching (5.5mm. long), the anlage separates

from its point of origin, as an ovoid mass of yolk-filled cells. By the growth of the copula and the other structures in its region, the anlage gradually splits longitudinally into right and left halves except for a small portion in front which persists for some time as the 'isthmus', holding the two halves together. Eight days later, (larva now 7mm. long), division is complete, the two halves being now separated by the developing sternohyoid muscle. From this point on irregularities occur, both in size and in details of the two halves, and the color of yolk content of the cells. A few cells (from four to six) may group themselves in an irregular clump in the mid-line in front of the halves; these Maurer interprets as remnant of the isthmus and calls it ' Nebenschilddrüse' or 'accessory thyreoid'. For a time it is difficult to follow the two halves in their subsequent development because of their loss of yolk content. (The writer has had the same difficulty in his material of Amblystoma of this stage). Cells arrange themselves in a solid cord on either side of the sternohyoid muscle. Later, (three or four weeks) these cell cords develop into follicles which show the presence of colloid. The external jugular vein lies a little ventral to the thyreoid in the adult, but the wonderfully complex network of blood vessels, of the adult does not develop in the larval stages.

He found the development of the thyreoid in Siredon pisciformis and Salamandra maculata similar to that in Triton taeniatus, and hence he concludes that the latter species furnishes a good example of the development of the organ in the urodeles in general.

Miss Platt ('96), finds one or two points of difference in Necturus maculosus, from the description given for Triton by Maurer. In Necturus, the thyreoid arises from the "base of the hyomandibular pocket, (not from the second, as stated by Maurer) directly above the oral fusion, and extends backward below the ventral aorta to a point where the mesoderm of the hyoid and mandibular arches unite in the medial plane". (p.561). In addition, "the cells separate from the

anterior part (isthmus of Maurer) of the outgrowth are taken into the mylohyoideus muscle and do not form accessory thyreoid" (p.567). The cells of the posterior portion are divided into two lines,and form neither solid masses or closed vesicles,and later (46mm.larva) they constitute a mass of vesicular tissue (thyreoid proper).

Bolau ('99) gives a description of the position of the thyreoid and thymus glands in adult amphibians,but has no account of their development. Livini ('02),describes the development of the thyreoid gland in Salamandrina perspicillata,which,in its essentials closely accord with Maurer's account of Salamandra maculata. He confirms the solid condition of the early anlage,typical of the urodeles. Maurer ('02),in Hertwig's Handbuch,gives briefly the results of his earlier work ('88),and mentions,in addition,that the gland had since been studied in Necturus (probably referring to Miss Platt's work),but other than this makes no further comment. Muthmann ('04),repeating some of the earlier work by Bracket ('98),followed the very early development of the thyreoid anlage in a number of urodeles--Triton alpestris,Axolotl,Salamandra atra --and also certain anurans,Bufo vulgaris and Rana temporaria-- with special reference to its position relative to the heart anlage. In Triton alpestris the anlage of the gland is laid down very early in the embryo (as early as the endothelium of the heart), and in a 20-21 somite specimen,it was a solid bud of cells on the floor of the pharynx,just in front of the bulbus arteriosus;later (25 somites),this elongated slightly and lay between the right and left mandibular arteries. In the 30 somite stage the caudal end had elongated a little,but the proximal end was still connected with the pharynx,and remained so for the first four days of larval life. Muthmann made no serious attempt to follow its development beyond this stage,remarking,p.43,-"Genauere Beschreibung dieser Vörgange geben Maurer und Livini".

Drüner ('04) notes the position of the thyreoid with reference to certain

adult structures in Siredon pisciformis,but contributes nothing to our knowledge of its development. Recently,Marcus ('08),has described the development of the thyreoid gland in Hypogeophis,where he found,instead of the solid early anlage (as in urodeles and some anurans),a hollow one,similar to that described by W.Müller ('71),for Rana,and Göette ('75) for Bombinator. He says,p.730, "Ein kompaktes solides Gebilde wird die Thyreoidea bei Hypogeophis nie,(stage 17) wenn auch in spateren Stadien (stage 22) nur ein Spalt oder auch nur die Kernanordnung auf die ursprüngliche Röhrenform hinweist".

Finally, Mrs. Thompson ('10),in a paper on the thyreoid and parathyreoids throughout the vertebrates,gives a very brief study of this gland in the amphibians. She bases her study on a single species of urodele (Spelerpes ruber, adult) and on the frog (mentions no genera nor species),and since she gives no details of the its development,only passing mention need be made here. She shows however,a drawing (pl.10,fig.4.) of the histological structure of the adult gland in Selerpes,which she claims is the first to be given for any urodele.

Thymus:

The position of the thymus in the adult amphibians,and something of its morphology in the various forms has long been known. Simon ('44), observed it in Necturus,Amphiuma and Cryptobranchus,and described its appearance and position in these forms. Soon after, Leydig ('53),in addition to the forms studied by Simon,described the structure in Proteus,Siredon,Caecilia annulata and a number of anurans. Its position,according to Leydig,is, in both the anurans and the urodeles colse behind the angle of the jaw,superficially placed beneath the skin. In the Caecilians,he noted four small bodies,one behind the other just behind the angle of the jaw. The nerve supply of the thymus was first noted by Fischer ('64),especially in Siredon pisciformis,being the cutaneus ramus of the vagus.

Göette ('75) was the first to study the development of the thymus in amphibians. He described it in Bombinator igneus as developing from the dorsal portion of the second gill-pouch,but at first he did not believe this to be the true thymus,preferring to call it the 'Halsdrüse'. Later, de Meuron, ('86) described the development in Bufo and Rana,as an epithelial body arising from the dorsal region of the second gill-pouch. This early separates from the rest of the epithelial cells,and soon contains cells which,in nature and appearance resemble those of the connective tissue. This he called the true thymus, and homologized it with the first thymus body of selachians. Maurer ('88),was the first to follow the development of it in the urodeles. He says," Die Entwicklung der Thymus bei Urodelen is unbekannt. Da nun dieses Organ in den verschiedenen Gruppen der Amphibien bei erwachsenen Thieren ein ganz ungleiches Verhalten zeigt,so fragt es sich sehr,ob seine Entwicklung eine gleiche ist". Maurer followed its development in Siredon pisciformis,Salamandra maculata and Triton taeniatus,and briefly stated,he found that in Siredon,five epithelial bodies were concerned in its genesis,the first two of which early degenerated and the three posterior ones remained. In Salamandra,three such epithelial bodies developed,which he thought could be looked upon as the homologues of the three persisting bodies in Siredon. In Triton,the anterior two early degenerated,while a single large bone-formed body remained some distance behind,which he was unable to follow in its developmental stages. Whether this was formed by the fusion of the three posterior bodies,as in the case of Siredon,or whether it was formed solely from the last he could not say. " Jederfalls ensteht die Urodelenthymus aus dorsalen Epithelknospen hinterer Kiemenspalten,wahrend die zweite Knospe,die bei Anuren die Thymus hervorgehen lässt,sich sehr früh mit der ersten Knospe rückbildet". Later, in Hertwig's Handbuch,('02) Maurer reviews briefly the development and position of the thymus bodies in Triton and Siredon,in which he corrects one or two points of his earlier work;these are

noted below in connection with Drüner's discussion.

Contrary to Maurer's description of the development of the thymus in the other urodeles, Livini ('02) finds the permanent thymus in Salamandrina to be the fifth larval body, formed from the fifth gill-pouch, and states that the bodies of the third and fourth as well as the first and second pouches degenerate early without leaving a trace.

In his work on the musculature and gill-region of the urodeles, Drüner ('04), touches upon the developmental relationships of the thymus in Siredon. He found as did Maurer, five thymus elements arising from the dorsal region of all five gill-pouches; of these the first two degenerate early, and the last three form the permanent thymus. In one or two cases he found a small follicular-like body persisting in the relative position of the first thymus body, which he interprets as a remnant of the same. According to him also, not only entoderm from the gill-pouches is concerned in the formation of the five primitive bodies, but ectoderm also contributes to their formation. On the other hand, he agrees with Maurer ('02), in locating the first body as lateral to the facial, rather than the Gasserian ganglion, and the second body lateral to the glossopharyngeal instead of the facial, as was stated by Maurer ('88). He also locates the third and fourth bodies with reference to the lateral branches of the branchial nerves of the vagus, rather than to the ganglion itself.

Marcus ('08), p.737, found thymus thickenings on the dorsal portion of six gill-pouches of Hypogeophis, those on the first and sixth, however, were rudimentary and degenerated early, while the other four pouches formed thymus bodies, which, after separating from the pharyngeal epithelium, became in the adult a four-lobed thymus gland, the lobes of which were separated by thin strands of connective tissue.

Of the two recent workers in the field of the histogenesis of the thymus gland in amphibians, Dustin ('11, on Axolotl, and '13, on Rana fusca) and

Maximow ('12,on Siredon pisciformis and Rana temporaria),only the latter gives a brief description of its morphogenesis. He finds the topography of the five early epithelial bodies in Siredon in essentially the same position as described by Maurer ('02),and,although he observes darkly staining cell groups, (what he calls the ' thymus ectodermalis ' von Drüner) closely associated with the thymus bodies on the one hand and with the corresponding ganglia on the other, (in the early stages--7.5 to 15mm. larvae),he is not certain of the origin of these,and he says,(p.573), " Ob diese Zellensammlungen wirklich dem Ektoderm enstammen,wie es Drüner will,vermag ich nich anzugeben---". The true epithelial charater of the bodies is retained but for a short time (from the 7.5 to the 9mm. stages),there soon appearing other elements (p.576),which increase in nùmbers in the 11mm. and subsequent larval stages. He also substantiates the results of the earlier workers (especially Maurer '88,and Druner '04) concerning the early degeneration of the first two epithelial bodies,and the persistance of the last three to form the definitive gland,although he carries his work only through the 25mm. stage,appending the remark,(p.603),"spateren Entwicklungsstadien der Thymus beim Axolotl boten für mich kein Interesse mehr---".

Postbranchial (Suprapericardial or Ultimobranchial) Body.

This structure,which has been given different names by different authors, was probably first described in the anurans (Rana and Bufo),by Leydig ('53) as parts of the true thyreoid. (Greil, ('05),says that Leydig described them as 'Glandes thyreoides accessories',but in Leydig's paper, I can not find that he mentions this name, and it is probable that Greil took this information from de Meuron who uses this term,see p.542). Van Bemmelen ('86)was the next worker who described the structure (in selachians) and from its position in that group gave to it the name 'suprapericardial body'. Later,de Meuron ('86), p.541,gave a brief account of its development in Bufo. According to him,it is symmetrical in development,arising from either side of the pharynx,as a small

diverticulum which soon forms isolated cysts lying on either side of the tracheal tube above the pericardium. In the adult, the cyst lying on either side was close to the thyreoid and was thus considered by de Meuron as ' accessory thyreoid',although he was unable to follow the details of development.

Maurer ('88),was the first to trace the development of the body in both Anura and Urodelia,and,because of its developmental position with reference to the branchial pouches,he gave it the name 'postbranchial body'. In the anurans (Rana and Bufo),the body develops symmetrically behind the fifth pouch,just lateral to the aditus laryngeus muscle,and consists of either single or complex follicles,which never contain colloid. They retain their early position close to the thyreoid,but according to Maurer,never unite with that gland in anurans. In the urodeles (Triton and Siredon),he found the body arising as a solid epithelial bud from the floor of the pharynx on the left side;this,after elongating,becomes separated from the pharynx,and takes a direction parallel to the long axis of the larval body. Late in development it acquires a lumen which never contains colloid. It does not in any way,according to Maurer,resemble the thyreoid,and therefore in his view can not be considered as an 'accessory thyreoid' as was de Meuron's belief. Maurer believed de Meuron described correctly the origin of the postbranchial body in Anura,but thought he confused its later development with the epithelial derivatives of the pouches,which later come to lie close to the adult thyreoid gland. Maurer agrees with de Meuron that the structure in Anura,is homologous with that of the selachians. The unilateral position of the body in the urodeles,which he studied,and the persistance of the connecting stalk with the pharynx,suggests to him that perhaps it represents a remnant of the ductus oesophago-cutaneus of Bdellostoma.

Miss Platt ('96),found that the body developed symmetrically on either side in Necturus,and thus pointed out that Maurer's conception of the asymmetrical development in the urodeles as a whole to be erroneous. In addition to this

she found that the structure arises as a small vesicle (in 15mm. larva), from the ventral floor of the pharynx on either side, not posterior to the fifth pouch (as was described by Maurer), but between the fourth and fifth pouches. Thus, the position of the body in Necturus as described by her, opposes the view of van Bemmelen, on the one hand, that they be regarded as 'rudimentary branchial clefts', and that of Maurer, that they are 'postbranchial' on the other. She therefore prefers to call them 'suprapericardial' rather than 'postbranchial'.

Maurer ('02), p.143, briefly reviews the development of the structure in amphibians, and while he contributes no new evidence of his own, he emphasizes the fact that it is to be regarded as a 'postbranchial' structure. He says, "Da er hier hinter der letzten Kiemenspalte liegt, eine Beziehung zum Pericard nicht besteht habe ich das Organ als postbranchialen Körper bezeichnet. Er liegt stets hinter der letzten Kiemenspalte, mag diese nun die 4, 5 oder 6 sein".

Drüner ('04), p.508, describes the postbranchial body in but a single stage of Siredon (3.6cm.) where it was a small ampulla-like structure, on the left side only formed by the insinking of the pharyngeal epithelium. In other series of the same form, he failed to find it.

Greil ('05) describes its development in Rana, Bufo and Hyla, and disagrees with Maurer's view that it is 'postbranchial', since it arises from the ventro-caudal region of a rudimentary sixth pouch, and is thus 'ultimobranchial'. The early anlage according to him is not formed by an out-pocketing of the pharyngeal epithelium, but by a simple thickening, which later develops a lumen. He agrees with van Bemmelen, that in the selachians, the body represents a rudimentary seventh pouch, but in the amphibians, where the seventh pouch is lost, the formation of the structure is assumed by the sixth, and so on in the higher groups as in mammals, the formation of the body is assumed by the last gill-pouch, the fourth.

In Hypogeophis, Marcus ('08), finds that the body develops symmetrically,

but is derived from the seventh pouch instead of the sixth as in the other amphibians; the sixth in this form apparently degenerating,(see p.723). He retains the name 'ultimobranchial' body and interprets it as a structure derived from the branchial,rather than from the postbranchial region of the pharynx.

At the Leipzig meeting of the Anatomische Gesellschaft,('11),Maurer defends his view in his discussion with Rabl in the following way (p.161),"Wahrend die von mir eingeführte Bezeichnung 'Epithelkörperchen' sich ganz eingebürgert hat,ist die Bezeichnung 'postbranchialer Körper'in die des ultimobranchialen Körpers umgeändert worden. Ich kann diese Aenderung nicht für glücklich halten. Es ist das betreffende Organ bei allen Wirbeltieren hinter der letzten Kiemenspalte vorhanden und zeigt aufsteigend eine fortschreitende Weiterbildung,im Gegensatz zu den Schlundspalten,die ganz schwinden. Es ist also das Gebilde etwas von den Schlundspalten Verschiedenes und liegt immer hinter der letzten Schlundspalte,darum ist es weniger präjudizierend,wenn man es als postbranchialen Körper bezeichnet".

The most recent contribution on the structure is that of Kingsbury ('14), who,although studying its development in mammals,especially man,gives a discussion of its significance and homology in the other vertebrates. He says,p. 609, " Three points remain indefinite---(1) its origin--whether it arises from branchial or postbranchial region of the pharynx. Dependent upon the answer to this question is the decision as to its designation as ultimobranchial,telobranchial,or postbranchial. (2)its fate; whether it persists within the thyreoid---(3) its value and interpretation as an organ or structure". He gives Grosser's view (a ductless gland which has become rudimentary),and objects to this on two points,namely; (1) that,"with the exception of the ultimobranchial body in birds,no gland has been found in the forms below the mammals with which the ultimobranchial body may be homologized ;" and (2),"that the ultimobranchial

bodies--if we use that term--of the different classes of vertebrates cannot themselves be directly homologized. He then cites Greil ('05,anurans),Tandler ('09,man) and Grosser ('10,man),where all agree that it is a derivative of a gill-pouch-- the first that of the sixth pouch,and the two latter that of the fifth pouch. "It is obvious that upon the interpretation of the ultimobranchial body as a branchiomeric organ,as a derivative of a rudimentary fifth pouch, the 'ultimobranchial' structures of the lower vertebrates cannot represent it, since the fifth pouch may be a functional gill-pouch in the amphibian". Rabl, ('11,13) suggestion that it is the representative of both fifth and sixth pouches in man,meets with Kingsbury's objection,since although it satisfies the homology between man and amphibians,"it fails as applied to the elasmobranchs where the sixth pouch is a functional gill cleft caudad of which occurs the suprapericardial body which appears to be an ultimobranchial body (van Bemmelen ('89),Greil ('05)".

" For those who view this structure as a vestigal ancestral gland of some kind,Maurer's term and interpretation inherent therein--Postbranchial body-- presents no such logical difficulty,since,as Maurer ('11) said in defense of his term at the Leipzig meeting of the Anatomische Gesellschaft,these structures might then be homologized throughout the vertebrate series in the forms in which they occur". The evidence,however,as Kingsbury sees it,"indicates strongly that the structures------belong to the branchial region and are not 'postbranchial' ". The only way then,"whereby these pharyngeal structures may be interpreted as ultimobranchial and also directly homologized in the different vertebrates would seem to be the assumption,--that it is the last branchial pouch which in the form of ultimobranchial body or represented by it as a derivative has retained its individual existance while the reduction in number of branchial pouches has been brought about by the elimination of the gill clefts that proceeded it in the series.

" The double assumption of this pharyngeal derivative as an 'ultimobranchial' body and as a vestigal gland representing an ancestral organ----cannot be true on any morphological basis of homology". Kingsbury thus concludes that in man, "no reason is seen for considering the ultimobranchial body-so called-either as representing an ancestral gland,vestigal in mammals,or representing any specific pouch,either V or VI,but merely formed by a continued growth activity in the branchial entoderm".

Epithelial bodies and gill-remnants.

Maurer ('88) was the first to describe the genesis of the small epithelial-like structures in close proximith to the glandulat structures in the neck of the adult amphibians,and was first to suggest that possibly these could be looked upon as the hologlogues of structures which occur in the higher forms. He found that the epithelial bodies develop during the time of the formation of the inner gills,from the ventral ends of the third and fourth pouches of the tadpole of the frog,while the gill-remnants, 'Kiemenreste',develop from the anterior ventral region of the branchial chamber at the time of the reduction of the gills. The carotid gland in Rana,according to Maurer,develops in a similar manner,from the ventral end of the second pouch,and was therefore considered by him as an epithelial structure. (This origin of the carotid gland has been doubed by other workers,especially Schaper ('96) and Zimmermann ('98).

Norris ('02),in following the development of the so-called ventral Kiemenrest of Maurer,in Rana fusca,is unable to agree that it is concerned in any way in its genesis with the branchial apparatus,but says that it arises (dur-

ing metamorphosis),in the region of the body previously occupied by parts of the basi-hyobranchialis muscle of the tadpole. In the urodeles,no such gill-remnants as occur in anurans have yet been described.

Maurer ('88) was the first to work out the development of the epithelial bodies in the urodeles. In Triton taeniatus,he found the bodies developed from the ventral portions of the third and fourth pouches,not during the larval stage as in the case of anurans,but during the metamorphosis,and these in the adult came to lie close to the lateral (convex) wall of the aortic arches. Maurer observed the formation of the carotid gland in the region of the second pouch,during this same period,but whether it developed from the cells of the transforming pouch he was unable to say. Although in the anurans,this seemed to him to be the case,he says in describing it in the urodeles,p.369,"Erst mit der Rückbildung des Kiemenapparates entwickeltsich die Carotidendrüse. Von dieser muss ich es dahin gestellt sein lassen,ob Epithelzellen sich an ihrer Bildung betheiligen".

Since Maruer wrote,very little work has been done on the development of the epithelial bodies and gill-remnants in the amphibians. Verdun ('98),refers to Maurer's work,and Mrs.Thompson ('10),gives but very brief discussion of them in her paper,where she prefers to call them parathyreoids. In the only urodele she studied (Spelerpes ruber),she found but a single body on either side,and this she does not trace in its development,but merely remarks on its small size (she was not able to find it with the naked eye) and gives only a brief description of its histology. She refers to Maurer in her account of the development (p.101) of this body in the anurans,but contributes nothing further of her own.

Morphology of the pharyngeal derivatives in other vertebrates.

As yet the problems of the homologies of the pharyngeal derivatives in the different groups of vertebrates are not settled and only brief statements of fact can be made here in the light of our present knowledge.

Thyreoid.

This,of all pharyngeal structures,is the easiest to homologize in the vertebrates,since,in all,it developd from the epithelium of the floor of the pharynx. Whether it is paired or unpaired,solid or hollow in its early anlage, and whether the morphology,physiology and histology of the adult gland is the same in all cases is not settled. Its development in the cyclostomes has been recently followed by Reese ('02),Cole ('05),Schaffer ('06) and Stockard ('06). In the ammocoete stage of the lamprey,it retains its connection with the pharynx,and it was homologized by W. Müller ('71),with the endostyle of the tunicates. In the later stage of the lamprey,as well as in the adult myxinoids the duct is lost,and the gland becomes follicular and its parts scattered in the region below the pharynx (Stockard,'06,in Bdellostoma).

In the elasmobranchs,Mrs Thompson,('10) finds a compact structure which she claims is partly epithelial,and partly adenoid in character; she suggests that possibly the adenoid portion corresponds to the 'parathyreoids' of the higher vertebrates. (So far as I have observed,no one has yet commented on this view in any way). In the teleosts (Gudernatsch '11),it has the same tendency to become broken into small isolated groups and scattered in the connective tissue,and is not an anatomical unit and is therefore not a gland in the sense of a compact structure.

In the reptiles,the gland is a single,lobate,follicular structure,which contains colloid and lies close to the trachea,but in the birds, it is paired, the halves lying close to the blood vessels and the side of the neck (Verdun '98)

large areas of which may be devoid of colloid (Mrs Thompson '10), and its vesicles are usually closely compact. Whether the anlage is single or double in the mammals, is not yet altogether settled, although Maurer ('02), states that the evidence seems to be in favor of the single origin, which would make it homologous with the gland in other vertebrates.

The parathyreoids, according to Verdun ('98), have their homologues in the 'epithelial bodies' of the amphibians, the latter having first been described by Maurer ('88), and with this identification I agree. (Concerning these structures more will be said below).

Thymus.

Whether the cyclostomes, like the gnathostomes have a true thymus is not settled. J.Müller ('43), p.115, was the first to describe a paired structure situated behind the gills, in the region of the heart in the myxinoids, which he, at that time, called 'Nebennieren'. Later, in an editor's note to Stannius' ('50) work on the thymus gland of the fishes, (p.507) he suggests that the 'Nebennieren' previously described by him corresponds to the thymus of the fishes, and thus it was that Stannius ('54) in his Handbuch, (p.256) says, "Die paarige Thymus is bischer bei den Myxinoiden-----beobachtet worden", and in a footnote on the same page he remarks, "Bei den Myxinoiden ist dies gebilde aufgefunden und beschrieben von J. Müller, der es zuerst als Nebennieren, später als Thymus deutete". The statement of Beard ('94), p.485, that " the only positive statement we possess emanates from Stannius", is not therefore exact, although his interpretation of this organ as a degenerate pronephros in Myxine, may be correct. Stockard ('06), p.99, in his study of the thyreoid in Bdellostoma, found no evidence of a thymus gland in any of the stages of development, and doubts its existence.

On the other hand, Schaffer ('94), discovered and described the development

of seven small bodies on the dorsal as well as the ventral region of as many pharyngeal pouches in Petromyzon, which he interprets as the thymus bodies in that form. Maurer ('02), however, points out that there is some doubt as to the homologies of these, and says, p.132, "Ob sie der Thymus höherer Wirbeltiere homolog sind, ob nur die dorsalen dafür anzusprechen sind, die ventralen aber als Epithelkorperchen zu deuten sind, ist nicht zu entscheiden: ja es ist möglich, dass sie nur den Cyclostomen zukommende Bildungen eigener Art darstellen, welche auf gnathostome Wirbeltiere nicht übergegangen sind".

In the gnathostomes, structures which have been interpreted as thymus bodies occur. Although arising from the endodermal epithelium of various number of gill-pouches (usually from the dorsal angle) these have been fairly well homologized in the different groups of vertebrates (mammals perhaps excepted). In the elasmobranchs, small thymus bodies develop from the dorsal angle of serer-al (second to sixth and possibly the spiracle) visceral pouches. In the few teleosts in which the development has been studied, and in the caecilians (Hypogeophis, Marcus '08), these develop from the second to sixth pouches. In the urodeles, they arise from pouches one to five, the first two usually degenerate, the last three persist to form the adult thymus. In the anurans, only the first and second pouches form such bodies, the second only persisting to form the definitive structure in the adult.

Comparatively little is known of the development of the thymus gland in the reptiles, but in the groups which have been studied, some differences are found. In certain of the lacertilia, Maurer ('99); Anguis, Gongylus, Lacerta, Saint-Remy and Prenant ('04), etc., the thymus bodies develop from the dorsal region of the second and third pouches, while in certain of the ophidians, (Coluber, Tropidontus), the third and fourth and possibly the fifth pouch form a thymus lobule. (For further details, see Maurer, '02, p.136).

In the birds, a similar condition prevails. According to de Meuron ('86)

and Mall ('87),only the third pouch forms a thymus body in the chick,while van Bemmelen ('86) and Verdun ('98) believe the fourth also forms thymus elements, and the lattor author thinks the fifth pouch contributes as well.

The thymus bodies in the mammals are developed from the ventral (rather than the dorsal) portion of the third and fourth pouches, and this fact throws considerable doubt on the homology of these organs in mammalian and non mammalian groups. In some cases also the ventral region of the second pouch (rabbit) has been described as forming a thymus body. Although it is beyond the scope of this paper to enter into a discussion of the intricate points of homology,brief reference may be made to the able discussion by Kingsbury ('15) pp.359-371. I quote his conclusions.

" Recognizing that the thymus-forming factors are not intrinsic,but extrinsic,i.e.,partly a function of position and relation,it is no longer necessary directly or completely to homologize thymus bodies in different forms,since it is obvious that different growth conditions may determine thymus development from quite different portions of the branchial epithelium,and portions that in one form may persist and undergo thymus transformation,in others may degenerate and disappear without the characteristic reaction appearing".

" In closing-------it may be stated that there is a wide-spread tendency to thymus-formation in the branchial region,characterized by a persistance and growth of epithelium with a characteristic (though not peculiar) reaction with adjacent tissues,under conditions that are not yet fully analizable. What these conditions are and what determines the development of a thymus or thymus bodies is unknown,and any attempt to determine them awaits further analysis of growth conditions of the region,particularly in the lower forms".

Postbranchial body.

This structure has not been described in the cyclostomes. It appears in

all elasmobranchs with the exception of Heptanchus, but is absent from all the teleosts yet studied. In the other gnathostomes, its appearance and position is variable, and its significance in these forms has lead to wide-spread discussion, as is evidenced by the different names and interpretations given it by various workers. Van Bemmelen, first discovered it in the elasmobranchs, and gave it the name of 'suprapericardial body'; then Maurer followed its development in the amphibians, and named it 'postbranchial body', and Greil, later, changed the name to 'ultimobranchial body'. Its phylogenetic significance is not clear. Some have suggested that it is the representative of the ductus oesophago-cutaneus of Bdellostoma; some think it represents a rudimentary gill-pouch, or that it is an ancestral gland of some sort; while others think that it is formed merely by continued vegetative growth of the branchial entoderm (see Kingsbury, '14, for latter view).

In the elasmobranchs it develops behind the sixth pouch, and is sometimes paired and sometimes single. In the amphibians it usually develops behind the fifth pouch, and is usually paired (anurans) or may be single (urodeles, Necturus excepted). In Bombinator igneus (anuran) according to Greil, '05, it is not developed on either side. In the lacertilia, it is sometimes single (van Bemmelen '86), sometimes paired (Maurer, '99), while in the snakes, it may be entirely absent (van Bemmelen). The relative position of its origin is a point upon which some differences are expressed; some authors interpreting it as developing from the pharynx behind the fourth pouch, and others, behind the fifth. In the birds and the mammals also, great diversity of opinions are expressed as to its position, significance and fate, but since certain phases of this have already been discussed, (see p. 63), a repetition here is not necessary.

Epithelial bodies and parathyreoids.

In all the gnathostomes thus far studied (elasmobranchs excepted, and if Mrs. Thompson's '10, contention is correct, in these forms as well), certain struct-

ures occur, which Maurer ('88) discovered in amphibians, and to which he gave the name 'epithelial bodies', the homologues of which, according to certain authors, have since been discovered in higher forms, but described under different names; parathyreoids (Sandström), glandules thyreoidea (Gley), etc. These structures develop from the ventral region of the third and fourth visceral pouches in the higher vertebrates, (reptiles, birds and mammals), and their homology to the epithelial bodies of the amphibians become at once apparent. Although embryologically and anatomically quite distinct and different in every way from the thyreoid, yet physiologically, in the higher froms at least, the parathyreoids become intimately associated with the former. This fact is strongly emphasized by Mrs. Thompson ('10, p.127), who says, " Thyreoid and parathyreoids are to be looked upon as structures of somewhat different embryological origin, which are anatomically separate and distinct in the lower vertebrata , but which come into very intimate anatomical and physiological relationships with each other in the mammalia". Their functions, so far as they are known, are very different.

IV. General Summary.

1. The anlagen of the thymus bodies are recognized in Amblystoma larvae 8mm.long, as epithelial thickenings at the caudal dorsal extremity of five pharyngeal pouches (counting the hyomandibular pouch as the first). These thickenings soon become solid epithelial bodies, which lose their early connection with the pharyngeal entoderm, and lie in the connective tissue dorsal to their respective pouches, and bear certain relationships in position to the ganglia of the cranial nerves and ear.

2. The darkly staining cells which are scattered or grouped about in the region close to the thymus bodies are regarded as mesenchymatous in origin and are not ectodermal contributions to the thymus bodies.

3. Of the five primitive epithelial thymus bodies, the first two degenerate early; this degeneration takes place with some irregularity in different individuals since in some larvae the second body had disappeared in the 11mm. stage, while the first still persisted as a very slender stalk of cells. Usually however, both bodies had disappeared by the 15mm. stage.

4. The three remaining bodies are, at first, small, spherical or slightly oval structures of about equal size (in 19mm. larvae, measuring 90x75mu, 75x60mu, and 90x120mu respectively) but during the later larval stages they increase gradually in size and elongate somewhat so that in larvae 45mm. long (the stage before transformation), they have the dimensions of 220x164mu, 180x240mu, and 285x350mu respectively.

5. The three bodies during the larval stages, lie close behind one another and caudo-lateral to the posterior wall of the ear. The third and fourth bodies are usually close together, while between the fourth and fifth bodies there is a much larger interval.

6. In the adult, the thymus gland is a three-lobed flattened structure

(probably formed by the union of the three larval thymus bodies) lying in the side of the neck, caudad and a little dorsal to the angle of the jaw. It is surrounded by loose connective tissue richly supplied with vascular vessels, and innervated by rami of the glossopharyngeal (IX) and vagus (X) nerves.

7. The anlage of the thyreoid gland is recognized in larvae 5mm. long, as a very shallow cup-like depression in the medial floor of the pharynx in the region of the hyomandibular pouch (not the second branchial pouch as Maurer '88 states for Triton) between the thickened oral plate, and the anterior limits of the pericardium.

8. As development proceeds, this cup-like anlage proliferates cells from its ventral surface so that in 8mm. larvae, a solid elongated stalk of cells reaches in a caudal direction toward the anterior wall of the pericardium a distance of about 100mu, but it does not unite with the latter in any way (differing in this respect from the similar formed structure described by Miss Platt in Necturus). A little later (9,5mm. larvae) the distal extremity of this solid stalk begins to divide into right and left halves, and this continues with some rapidity so that in 10mm. larvae it is completed, and in addition, the anterior connection with the pharynx is lost, and the two halves lie lateral to the geniohyoideus muscle of either side.

9. I find no evidence that the cells which formed either the isthmus of the two halves of the thyreoid, or those which formed the connecting stalk persist to form accessory thyreoids as was described by Maurer in Triton, and thus Amblystoma more nearly agrees with the condition in Necturus as described by Miss Platt.

10. After becoming completely divided into right and left halves, each half loses its solid and compact condition. The epithelial cells scatter loosely into the connective tissue and arrange themselves irregularly about

the dorsal wall of the inferior jugular vein of either side (larvae 13mm. long) and from these loosely scattered epithelial cells the follicles of the gland subsequently arise by mitotic division.

11. Follicles first appear in larvae 15mm.long; they are either globular or elliptical,with a well defined outer layer of cuboidal cells enclosing a conspicuous cavity,probably containing a fluid of some sort but no colloid. They vary greatly in size,but,as a rule,they enlarge as development proceeds,varying from 19 to 36mu in diameter in 19mm.larvae,to about 100mu in length and between 50 and 75mu in breadth in the late larval and early transforming stages.

12. A sort of membrana propria appears late in the larval life; it surrounds not only the follicles and the intervening lymph spaces,but also envelops the inferior jugular vein in the region of the thyreoid gland.

13. A so-called rete mirabile of the inferior jugular vein fails to develop during the whole of the larval period,and so far as the writer is able to learn from careful study of developmental stages,the external carotid artery has no direct connection with the gland in any of the larval stages.

14. Colloid appears rather late in the larval stages,the first evidence of it being seen in larvae 39 or 40mm.long.

15. With the transformation of the ventral gill-region,the thyreoid gland is pushed a little laterally and caudally,so that it lies in the space just in front of the anterio-lateral wall of the pericardium,and,in the adult,it is flanked medially by the geniohyoideus,laterally by the hyoideus internus of the first branchial arch,and dorsally by the sternohyoideus muscles.

16. From the condition of the follicles in the late transforming and early adult gland,it is evident that new and smaller follicles are being bud-

ded from the larger ones.

17. The blood supply of the adult gland is from small venous twigs from either the sternohyoideus or geniohyoideus muscles (never from the large inferior jugular trunk),which upon entering the gland break up into numerous smaller vessels ('rete mirabile') and which join the jugular vein some distance caudad. Its connection with the external carotid artery is very doubtful,in only a single case did a small twig (probably the thyreoid artery) pass into the vascular network of the gland.

18. The earliest stage in which the anlage of the postbranchial body is recognized in my material is in larvae 8mm.long. It develops as a rule (in single individual 19mm.long on the right side as well) on the left side. In its early condition it is a thickening of a certain portion of the pharyngeal floor,lying (in sections with the vagus ganglion) between the anlage of the fourth branchial (fifth visceral) pouch and the anlage of the glottis, and protruding slightly ventrally toward the dorsal wall of the pericardium. It is thus 'postbranchial' as Maurer claimed for the similar structure in Triton,and appears in the relative position of a sixth pouch.

19. In 9.5mm.larvae,the anlage makes a solid cylindrical stalk of cells (about 40mu long,and between 25-30mu thick) extending vertically downward from the floor of the pharynx. It soon elongates,loses its connection with the pharynx (11-13mm.larvae),and as anirregular,poorly defined mass of cells extending in an anterio-posterior direction lies medial to the aditus laryngeus muscle.

20. In one 19mm.larva,a postbranchial body was found on the right as well as on the left side;the left however was the larger. This is an unusual condition,since in none of the other specimens studied did the structure on the right side occur,but is of interest since it shows the possibility of some variability within a genus of urodeles. It is also important as bearing

upon the questions of homologies of these structures.

21. In the later larval stages, the postbranchial body becomes very irregular;in some regions it is solid,in other parts it shows follicular structure,with cuboidal cells forming a fairly definite layer enclosing a conspicuous lumen,but which in no case contains colloidal material.

22. During transformation,because of increase in size of the surrounding structures (especially the laryngeus and sternohyoideus muscles) the postbranchial body is flattened laterally and reduced to a sheet of poorly defined cells which now contains no lumen.

23. In my material,the structure and anatomical position of the postbranchial body in the adult is variable. I was unable to find it by gross dissection. In sections of young adult heads,it is a fairly compact oval body composed of fairly regular cuboidal cells enclosing a spacious lumen. In sections of old heads,I was not able with certainty to locate the structure.

24. The carotid gland and epithelial bodies in Amblystoma begin their development at the time of metamorphosis. There is no evidence to show that the carotid gland is concerned in its genesis with the epithelial cells of the degenerating gill-pouches.

25. The anlagen of the epithelial bodies (two on either side) are recognized as irregular longitudinal sheets of entodermal cells (remnants of the ventral portions of the fourth and fifth visceral pouches) extending caudad (caudal limits poorly defined) from points where the afferent branchial arteries enter their corresponding gills in the early transforming stage.

26. As transformation proceeds,the irregular longitudinal sheets of entodermal cells become resolved into compact oval bodies (two on a side) so that in the late transforming stage,these lie one behind the other,close caudad to the carotid gland,each being enveloped by a connective tissue covering. They now take a position lateral to the second aortic arch.

27. The two epithelial bodies are easily exposed in the Adult by gross dissection. They lie embedded in connective tissue on the side of the neck in the region just below the thymus gland, just caudad to the carotid gland, although their position may vary slightly in different individuals.

28. The blood supply of the epithelial bodies is from small twigs of the second aortic arch, and from the external carotid artery, while they are innervated (probably) by a small ramus from the vagus ganglion.

V. Bibliography.

Anderson,O.A. 1894 Zur Kenntniss der Morphologie der Schilddrüse. Arch.f.Anat. u.Phys.,Anat.Abt., pp.177-224.

Baber,S.C. 1876 Contributions to the minute anatomy of the thyreoid gland of the dog. Phil.Trans.R.Soc. Lon., 166,Part 2,p.557.

1881 Researches on the minute structure of the thyreoid gland. Phil. Tran.R.Soc.Lon., 172,p.577.

Beard,J. 1894 The development and probable function of the thymus. Anat. Anz., 9,pp.476-486.

Bemmelen,J.F. van 1886 Über vermutliche rudimentäre Kiemenspalten bei Elasmobranchiern. (Über die Suprapericardialkörper). Mitt.Zool.Stat.Neapel., 6.

1886 Die Visceraltaschen und Aortenbogen bei Reptilien und Vögeln. Zool.Anz.Nr.,231 u.232.

1889 Über die Suprapericardialkörper. Anat.Anz.,4. pp.400-407.

Boas,E.V. 1882 Über den Conus Arteriosus und die Arterienbogen der Amphibien. Morph.Jahrb., 7.p.488.

1883 Beiträge zur Angiologie der Amphibien. Morph.Jahrb., 8.

Bolau,H. 1899 Glandula thyreoidea und Glandula thymus der Amphibien. Zool. Jahrb.,12.pp.657-710.

Born,G. 1883 Ueber d. Derivate der embryonalen Schlundbogen und Schlundspalten. bei Säugethieren. Arch.f.Mikr.Anat., 22. p.310.

Brachet,A. 1898 Recherches sur le développement du coeur,des premiers vaisseaux et du sang chez les amphibiens urodèles. Arch.d'Anat.Micros. T.1, fasc.II.,p.251.

Coghill,G.E. 1902 Cranial nerves of Amblystoma tigrinum. Jour.Comp.Neur.,12, p.207.

Cole,F.J. 1905 Notes on Myxine. Anat.Anz.,27,pp.323-326.

Cope,E.D. 1889 Batrachians of No.America. Bul.Nat.Museum, 34.

Drüner,L. 1904 Studien zur Anatomie der Zungenbein-Kiemenbogen- und Kehlkopfmusculatur der Urodelen. II Teil. Zool. Jahrb. Abt.f.Anat. u. Ontog. d.Thiere.,19.,pp.361-690.

Dustin,A.P. 1911 Le Thymus de l'Axolotl. Arch.d.Biologie.,26,p.557.

1913 Recherches d'histologie normale et expérimentale sur le thymus des Amphibiens Anoures. Arch.d.Biologie.,28.,pp.1-110.

Fischer,J.G. 1864 Anatomische Abhandlungen über die Perennibranchiaten und Derotremen. Hamburg. 1864.

Forsyth, D. 1908 The comparative anatomy,gross and minute,of the thyreoid and parathyreoid glands in mammals and birds. Jour. Anat.and Phys.,42.

Gley, E. 1891 Sur les fonctions du corps thyreoid. Compte.Rend.Soc.Biol.Paris, Ser.9,Tome III,pp.841-847.

Göppert,E. 1902 Die Entwickelung des Mundes und der Mundhöhle mit Drüsen und Zunge; etc., Handbuch der Entwickelungslehre der Wirbeltiere.,Bd.II, Teil,I.

Göette,A. 1875 Entwickelungsgechicte der Unke. Leipzig 1875.

Greil,A. 1904 Über die sechsten Schlundtaschen der Amphibien und deren Beziehungen zu den suprapericardialen(postbranchial) Körpern. Anat. Anz., 25,pp.136-137.
1905 Über die anlage der Lungen,sowie der ultimobranchialen (postbranchialen,suprapericardialen) Körper bei anuren Amphibien. Anat. Hefte.,29,pp.445-506.
1906 Ueber die Homologie der Anammierkiemen. Anat. Anz.,28,p.257.
1906 Über der Entstehung der Kiemendarmderivate von Ceratodus F. Verh. d.Anat.Gesel.Vers.zu Rostok. 1906. Also in Anat.Anz.,29,pp.115-131.

Grosser,O. 1910 Zur Kenntnis des ultimobranchial Körper beim Menschen. Anat. Anz.,37,pp.337-342.
1911 Die entwickelung des Kiemendarms und des Respirationsapparates. Keibel and Mall, Handbuch der Entwickelungsgeschicte des Menschen. 2,pp.446-482.

Gudernatsch,J.F. 1911 The thyreoid gland of the Teleosts. Jour. Morph.,21,p. 709.

Herrick,C.J. 1894 The cranial nerves of Amblystoma punctatum. Jour. Comp.Neur., 4,pp.193-220.

Hammar,J.A. 1908 Glandula parathyreoides (Sandström) En historisk öfverblink. Hygiea. Festband. 1908.
1909 Zur Kenntnis der Teleostierthymus. Arch.f.Mikr.Anat.,73,p.1.
1909 Fünfzig Jahre Thymusforschung. Erg.d.Anat.u.Entwickl.v.Merkel und Bonnet, Bd.,19.
1913 Zur Nomenklatur gewisser Kiemenderivate. Anat.Anz.,43,p.145.
1914 Zur Kenntnis der Elasmobranchier-thymus. Zool. Jahrb.,32,p.135.

Johnston,J.B. 1910 The limit between ectoderm and entoderm in the mouth,and the origin of Taste Buds. I. Amphibians. Am.Jour.Anat.,10,pp.41-67.

Kingsbury,B.F. 1914 On the so-called ultimobranchial body of the Mammalian embryo. Man. Anat.Anz.,47,pp.609-627.
1915 The development of the human pharynx. I.The pharyngeal derivatives. Am. Jour. Anat., 18,pp.329-386.

Kingsley,J.S. and Thyng,F.W. 1904 The Hypophysis in Amblystoma. Tufts Col. Studies.,#8,v.I,pp.363-378.

Kohn,A. 1895 Studien uber die Schilddrüse. Arch.f.Mikr.Anat.,44.
1900 Die Epithelkörperchen. Anat.Hefte.,2Abth.,9.
1900 Ueber den Bau und die Entwicklungs der sogenannten Carotisdrüse. Arch.f.Mikr.Anat.u. Entwick., 56.

Leydig, Franz. 1853 Anatomisch-Histologische Untersuchungen über Fische und Reptilien. Berlin, 1853.

Livini,F. 1902 Organi del sistema timo-tireoideo nella Salamandrina perspiciliata. Archivo.Italiano.d.Anat.e.d. Embryo.,I, Fasc.I.

Mall,F.P. 1887 Entwicklung der Branchialbogen und spalten beim Hühnchen. Arch. f. Anat. u.Entwickl.,Bd.I,pp.1-34.

Marcus, H. 1908 Beiträge zur Kenntnis der Gymnophionen. I. Über das Schlundspaltengebiet. Arch.f.Mikr.Anat.u.Entwickl.,71.

Maurer, F. 1886 Schilddrüse und Thymus der Teleostier. Morph.Jahrb.,11.
1888 Schilddrüse,Thymus und Kiemenreste der Amphibien. Morph.Jahrb., 13,pp.296-377.
1888b Die Kiemen und ihre Gefässe bei anuren und urodelen Amphibien, u.s.v. Morph. Jahrb.,14.
1899 Die Schilddrüse,Thymus und andre Schlundspaltenderivate bei der Eidechse. Morph. Jahrb.,27,
1902 Die Entwicklung des Darmsystems. I.Die Kiemenspalten und ihre Derivate. O.Hertwig's Handbuch der vergl. und exp.Entwick. Jena 1906. pp.109-250.
1911 See Rabl,H.,below.

Maximow,A. 1912 Untersuchungen über Blut und Bindegewebe. IV.Über die Histogenese der Thymus bei Amphibien. Arch.f.Mikr.Anat.,79,pp.560-611.
1913 Über die embryonale Entwicklung der Thymus bei Selachiern. Arch. f.Mikr.Anat.,80.

Mayer,S. 1888 Zur Lehre von der Schilddrüse und Thymus bei den Amphibien. Anat. Anz.,3,No.4 und 5.

Mayr,Th. 1912 Die Entwickelung der Drüsen innerer sekretion: Thymus und Tholus der Säuger. Morph. Jahrb.,45,pp.1-56.

Meuron,P. de 1886 Recherches sur le développement du thymus et de la glande thyreoide. Recueil. Zool. Suisse. I Ser.,v.3,pp.517-628.

Müller, J. 1843 Vergleichenden Anatomie der Myxinoiden. (Schluss). Abhand.d. Akad.d. Wiss. Berlin.,1843-p.109.

Müller, L.T. Beiträge zur Histologie der normalen und der erkrankten Schilddrüse. Beiträge z.path.Anat.u.Allg.Path.(Ziegler's), 19,p.127. 1892.

Müller, W. 1871 Ueber die Entwicklung der Schilddrüse. Jenaische Zeitschr.f. Med.u.Naturw., 6, 1871.

Muthmann, E. 1904 Über die erste Anlage der Schilddrüse und deren lagebeziehung zur ersten anlage des Herzens bei Amphibien. Anat.Hefte.,26,I.pp.1-47.

Norris,H.A. 1902 The origin of the so-called "ventraler Kiemenreste" and the Corpus propericardiale of the frog. Anat.Anz.,21,pp.433-442.

Pensa, A. Osservazioni sulla struttura del Timo. Anat.Anz.,27,pp.529-541. 1905.

Platt,Miss J.B. 1896 The development of the thyreoid gland and suprapericardial bodies in Necturus. Anat. Anz.,11,pp.557-567.

Rabl,H. 1911 Ueber die Abkömmlinge der Kiementaschen und das Schicksal der Halsbucht beim Meerschweinchen. (See Maurer's discussion,p.161). Anat. Anz.,38,pp.157-161.
1913 Entwickl.der Derivate des Kiemendarms.Arch.f.Mikr.Anat.,82.

Reese,A.M. 1902 Structure and development of the thyreoid gland in Petromyzon. Pro. Acad.Nat.Sci.Phila.,54,pp.85-102.

Saint-Remy,G. et Prenant,A. 1904 Recherches sur le développement des dérivés branchiaux chez les Sauriens et les Ophidiens. Arch. de Biol.Paris., 20,p.145.

Sandström,J. 1880 Über ein neue Drüse beim Menschen und bei verschiedenen Säugetiere. Hofmann-Schwalbes Jahresber. 1881, Bd.9.,224-226.

Schaffer,Josef. 1894 Über die Thymusanlage bei Petromyzon Planeria. Sitzungs. Akad. der Wissensch. Mathe-Naturwiss.,Wien.,1894, Ab.III.,p.149.

1906 Berichtigung die Schilddrüse von Myxine betreffend. Anat.Anz.,28,p.65.

Schaper,A. 1896 Ueber die sogenannten Epithelkörper (gland parathyreoideae) in der seitliche Nachbarschaft der Schilddrüse und der Umgebung der Arteria Carotis der Säuger und des Menschen. Arch.f. Mikr.Anat.,46, p.239.

Stockard,Ch.R. 1906 The development of the thyreoid gland in Bdellostoma Stouti. Anat. Anz.,29,p.91.

Simon,J. 1844 On the comparative anatomy of the thyreoid gland. Phil.Tran. R. Soc. Lon., 134,p.295.

1845 A physiological essay on the thymus gland. London. 1845.

Stannius, H. 1850 Ueber eine der Thymus entsprechende Drüse bei Knochenfischen. Müller's Arch.,1850,pp.501-507.

1854 Handbuch der Zootomie von Siebold und Stannius. 2 Teil,I Heft.

Siebold,von. und Stannius,H. 1856 Handbuch der Zootomie. Berlin 1856.

Strong,O.S. 1895 The cranial nerves of Amphibians. Jour.Morph.,10,pp.101-230.

Thompson,Mrs F.D. 1910 The thyreoid and parathyreoid glands throughout the vertebrates with observations on some closely related structures. Phil. Trans. R. Soc. London. Series B.,CCI.,pp.91-132.

Tandler,J. 1909. Uber die Entwicklung des 5 Aortenbogens und der 5 Schlundtasche bei Menschen. Anat. Hefte.,38.

Vialleton,L. Sur les arcs vicéraux et leur role topographique chez les vertébrés. Arch.d'Anat. Micro.,10,pp, 1-122. 1908.

Verdun,P. 1898 Dérivés branchiaux. Contribution a l'étude des dérivés branchiaux chez les vertébrés supérieurs. Thèse. Toulouse. 1898.

1898b Glandules branchiales et corps post-branchial chez les Reptiles. Comt. Rend. Soc.Biol.Paris., Serie 10,T.5,p.1046.

1898c Sur les dérivés branchiaux du poulet. Comp.Rend.Soc.Biol. Paris. Serie 10,T.5,pp.243-244.

Wiedersheim, R. 1879 Die Anatomie der Gymnophionen. Jena, 1879.

1884 Grundriss der vergleichenden Anatomie der Wirbeltiere. Jena,1884

Zimmermann,W. 1898 Beiträge zur Kenntniss einiger Drüsen und Epithelien. Arch.f.Mikr. Anat.,52,p.552.

VI. Description of Plates and Figures.

A. Abbreviations.

a.a_{1-4}- aortic arches.
a.b.a_{1-4}- afferent branchial arteries.
a.l.- aditus laryngeus muscle.
ao- dorsal aorta.

br.$_{1-5}$- branchial pouches.

c.br.$_{1-4}$-branchial cartilages.
c.g.- carotid gland.
co.-copula..

d.c.- Cuvarian duct.
d.i.- digastric muscle.
d.l.- dorso-laryngeus muscle.

e.- epithelial cells.
e.b.$_{1,2}$- epithelial bodies.
e.b.a.$_{1-4}$- efferent branchial arteries.
e.c.-external carotid artery.
e.j.- inferior (external) jugular vein.

fol.-thyreoid follicles.

g.hy.- geniohyoideus muscle.

ht.- heart.
hy.- hyoid.
hy.m.- hyomandibular pouch.

i.c.- internal carotid artery.
i.j.- internal jugular vein.

l.- lateralis nerve of the vagus.
lat.d.-latissimus dorsi muscle.
l.br.-levator branchiarum muscles.
l.s.-levator scapularis muscle.

ma.- mandibular artery.
mas.- masseter muscle.
m.c.- Meckel's cartilage.
m.hy.- mylohyoideus muscle.
m-p.- mandibular-pectoralis muscle.

n.-notochord.
n.$_{1,2,3}$- branchial nerves.

p.a.- pulmonary artery.
pb.- postbranchial body.
ph.- pharynx.
pro-h.- pro-corico-hyoideus muscle.

st.- stomodeum.
s.v.- sinus venosus.

t.$_{1-5}$- thymus bodies, and gland.
te.- temporalis muscle.
tp.- trapezius muscle.
tr.- thyreoid anlage or gland.

v.a.- ventral aorta.
v.v.- vascular vessels.

VII.-facial ganglion.

IX.- glossopharyngeal ganglion.

X.- vagus ganglion.

1.- cartilage of the first arch.

2.- cartilage of the second arch.

3.- cartilage of the third arch.

4.- cartilage of the fourth arch.

Explanation of Figures.

Plate I.

1. Medial sagittal section of 5mm.larva showing relation of the early thyreoid anlage (tr.) to the oral plate and the pericardium. (x50)

2. Transverse section on line a-a, of fig.1., showing the thyreoid anlage (tr.) projecting between the mandibular arteries of the two sides. (x50)

3. Enlarged portion of fig.2. (x200)

4. Medial sagittal section of 8mm.larva, showing the now elongated thyreoid anlage and its relation to the ventral mesoderm (co.) and the pericardium. (x50)

5. Transverse section along line b-b, of fig.4., showing cells of the stomodeum and the thickened oral plate.(x50).

6. Transverse section of 8mm.larva, along line c-c, of fig.4.; the anlage of the thyreoid (tr.) still connected with the pharynx. Anlage of first thymus body (t_1) is at the dorsal lateral angle of the hyomandibular pouch, and below the facial ganglion. (VII) (x50)

7. Transverse section of 8mm.larva, along line d-d, of fig.4., showing the thyreoid anlage (tr.), ventral mesoderm (co.) and anlage of the geniohyoideus muscle (g.hy.) of either side. (x50)

8. Transverse section through the anlage of the second thymus body (t_{II}) of 8mm. larva. It arises from the entodermal cells of the dorsal angle of the first branchial pouch ($br._1$), and lies lateral and ventral to the glossopharyngeal ganglion (IX) (x50)

9,10,11. Transverse sections showing the anlagen of the third, fourth and fifth thymus bodies of 8mm. larva respectively. (t_{III}) (t_{IV}) (t_V). (x50).

10a. Transverse section of 8mm.larva, showing the anlage of the postbranchial body at this stage. (x200)

12. Transverse section through the anlage of the first thymus body (t_I) of 9.5mm. larva. This section also shows the unpaired thyreoid (tr.) between the geniohyoid muscles; the copula lies just above it in the medial line. (x50)

13. Transverse section through the caudal extremity of the thyreoid of 9.5mm. larva, showing its division into right and left halves in this region, the copula dipping ventrally between the two. (x50)

14. Transverse section showing the second thymus body (t_{II}) of 9.5mm.larva completely severed from the pharyngeal entoderm, and lying dorsal to the pharynx, medial to the levator muscle of the second arch. (x50)

15. Transverse section showing the third thymus body (t_{III}) of 9.5mm.larva in connection with the pharyngeal epithelium in the region of the dorsal extremity of the second branchial pouch. The anlage of the postbranchial body (pb.) is also

shown. (x50)

16,17. Transverse sections showing the position of the fourth and fifth thymus bodies (t_{IV})(t_V) of 9.5mm.larva in relation to their respective pharyngeal pouches. (x50)

18. Transverse section showing the now much reduced finger-shaped first thymus body (t_I) of the 10mm.larva. It protrudes dorsally from the pharynx and reaches almost to the ventral surface of the facial ganglion,which lies just above it in this region. (x50)

19. The same thymus body enlarged (x200),showing large epithelial cells similar to those of the pharynx. It is connected directly with the pharynx by a slightly constricted stalk.

20. Transverse section showing the postbranchial body of 10mm.larva. (x50)

21. Transverse section through the fifth thymus body of 11mm. larva. (x50)

22. Section through the fifth thymus body of 11mm.larva much enlarged (x200), showing the large epithelial cells embedded in the surrounding connective tissue.

23. Transverse section through the anterior region of the thyreoid gland of a 19mm. larva,showing the position of three thyreoid follicles placed about the dorsal wall of the inferior jugular vein. The external carotid artery is somewhat dorso-lateral. (x95)

24. Section showing the three thyreoid follicles of fig.23.,in more detail. (x200).

25. Transverse section showing the relative position of the postbranchial body, (pb.) of 19mm.larva. (x50).

26. Transverse section through the third thymus body (t_{III}) of a 19mm. larva. (x50)

Plate II.

27, 28. Transverse sections showing the relative positions of the fourth and fifth thymus bodies (t_{IV}) (t_V) of a 19mm.larva. (x50)

29. Transverse section through the central region of the third thymus body of 25mm.larva,showing the comparatively few large epithelial cells forming the margin of the body,within which is a conspicuous space. Note there is as yet no connective tissue envelop about the margin,tho cells are simply embedded in loose connective tissue cells. (x200)

30. Transverse section through the central portion of the third thymus body of a 35mm.larva,showing the now scattered smaller epithelial cells surrounded by a connective tissue envelop. (x200)

31. Transverse section through the central region of the thyreoid gland of

of a 45mm.larva, showing the arrangement of the thyroid follicles (fol.) to one another, and to the vascular and lymph vessels (v.v.). Note that the inferior jugular vein (e.j.) is almost surrounded by the follicles, and is enclosed like them with the "membrana propria" of the connective tissue, while the external carotid artery (e.c.) is not thus envelopod. (x200)

32,33,34. Transverse sections through the third, fourth and fifth thymus bodies (t_{III}) (t_{IV}) (t_V) of an early transforming larva. Note the condition of the now transforming pharyngeal pouches. (x15)

35. Transverse section through the head of a young adult, showing the position of the second epithelial body ($e.b._2$), and the thymus gland (t). (x15)

36. Schematic ventral view of the head of a young adult, showing the relative positions of the thyreoid (tr) thymus (t) glands and epithelial bodies (e.b.), to the blood vessels and the muscles of the region. (x4)

37. Lateral view of adult showing the position of the three-lobed thymus gland. (x4)

38. Wax reconstruction showing the relationships of the postbranchial body (pb.) of a 19mm.larva. (x50)

39. Transverse section showing the early anlagen of the epithelial bodies ($e.b._{1,2}$) (x25)

40. Schematic lateral view of the head of adult, showing the position of the thymus (t) and thyreoid (tr.) glands, epithelial bodies (e.b.) and the blood vessels. (x4)

41. Wax reconstruction of the three thymus bodies of a 19mm.larva, (dorsal view of right side), showing their relative position to the branchial cartilages, (1,2,3,4) blood vessels, and nerves of the region ($n._{1,2,3}$). (x50)

42. Wax reconstruction of the region of the epithelial bodies (e.b.) of a young adult on the left side, showing their relation to the blood vessels, carotid gland, thymus and thyreoid glands, etc. (x50) (See also fig.35, in section)

43. Wax reconstruction of the thyreoid gland of an early transforming larva, showing the relation of follicles one to another, and to the external (inferior) jugular vein, and the small medial twig from the sternohyoideus muscle, which forms a rete mirabile within the follicular mass. Note the large size of follicles. (See fig.31, which is a cross section of this gland for details of the internal relationships) (x62)

44. Wax reconstruction of the left postbranchial body of 26mm.larva, from above (x200)

45. Wax reconstruction of the thyreoid anlage of 8mm.larva, showing its connection with the pharyngeal epithelium anteriorly at the point where the hyomandibular pouch is extending laterally. Notice also, the position of the copula (co.) and the hyoid and first branchial cartilage anlagen just dorsal to it. (x50)

46. Wax reconstruction of the hyoid apparatus of the late transforming larva which is almost that of the adult condition, showing the relative positions of the thyreoid (tr.) and thymus (t) glands to the cartilages. (x50)

47. Wax reconstruction of the ventral pharyngeal region of 39mm. larva, (right side), showing the position of the thyreoid gland in this stage to the branchial cartilages and blood vessels. (about x30)

VII. Vita.

Francis Marsh Baldwin was born at West Upton, Massachusetts, January 16th., 1885, and attended the graded and high schools of that place, graduating from the high school in June 1903. His undergraduate work was done in the Collegiate department of Clark University, at Worcester, Massachusetts, and he was graduated from the same in June 1906, with the degree of Bachelor of Arts. After pursuing studies in biology and psychology, in Clark University, he received the degree of Master of Arts in June 1907.

During the years 1908-1911, he was Instructor in Nature and Science in Louisville, Ky., Normal School, and from that position went to the position of Professor of Biology and Chemistry in Western Maryland College, Westminster, Maryland, which position he held during the years 1911-1915. During 1915-1917, he has been Assistant in Zoology and a Graduate Student at the University of Illinois. In the summer of 1916, he was Assistant in the Summer Session at the University of Illinois.

The summer of 1914, was spent as a student at the Marine Biological Laboratory at Woods Hole, Massachusetts, working on the embryology of certain marine forms. The summer of 1915, was spent at the U.S. Bureau of Fisheries Laboratory at the same place, as a research student, working on the, "Consumption of Oxygen by Marine forms", this data is to be published jointly with Professor G.G. Scott, of the College of the City of New York.

Published in loose-leaf form," Description of the Chemical Elements", (Mather Printing Co., Balto., Md.) 1914, and has had accepted for publication in the Journal of Animal Behavior, " Diurnal Activity of the Earthworm".

PLATE I.

1
n
ph.
tr.
st.
3
eye
5
st.
d
c
b
n
ph.
co.
d
tr.
c
b
6
VII
i.c.
m.hy
tr.
7
ear
co.
tr.
ghy.
m.hy
2
ph.
tr.
ma.
22
8
IX
br.1
9
X
br.2
10
X
i.j.
e.ba.
br.3
11
l.
br.4
sv.
10a
pb.
br.4
12
VII
hy.m.
hy.
br.1
co.
tr.
14
IX
l.br.
br.2
br.3
13
VII
i.c.
c.br.1
hy.m.
hy.
br.1
c.o.
e.c.
tr.
15
X
e.br.a.
br.2
br.3
br.4
pb.
a.br.a.
ej.
16
X
l.br.
br.3
br.4
17
l.br.
dl.
ao.
d.c.
18
VII
mas.
e.br.a.
hy.
24
19
20
te
X
i.j.
pb.
cbr.
23
cbr.1
e.c.
shy.
tr.
ej.
co.
g.hy.
26
X
lbr.
eba.
cbr.
21
l.
ao.
dl.
d.c.
25
a.l.
pb.
eba.
lbr.
cbr.
aba.

LIBRARY
OF THE
UNIVERSITY OF ILLINOIS

PLATE II.

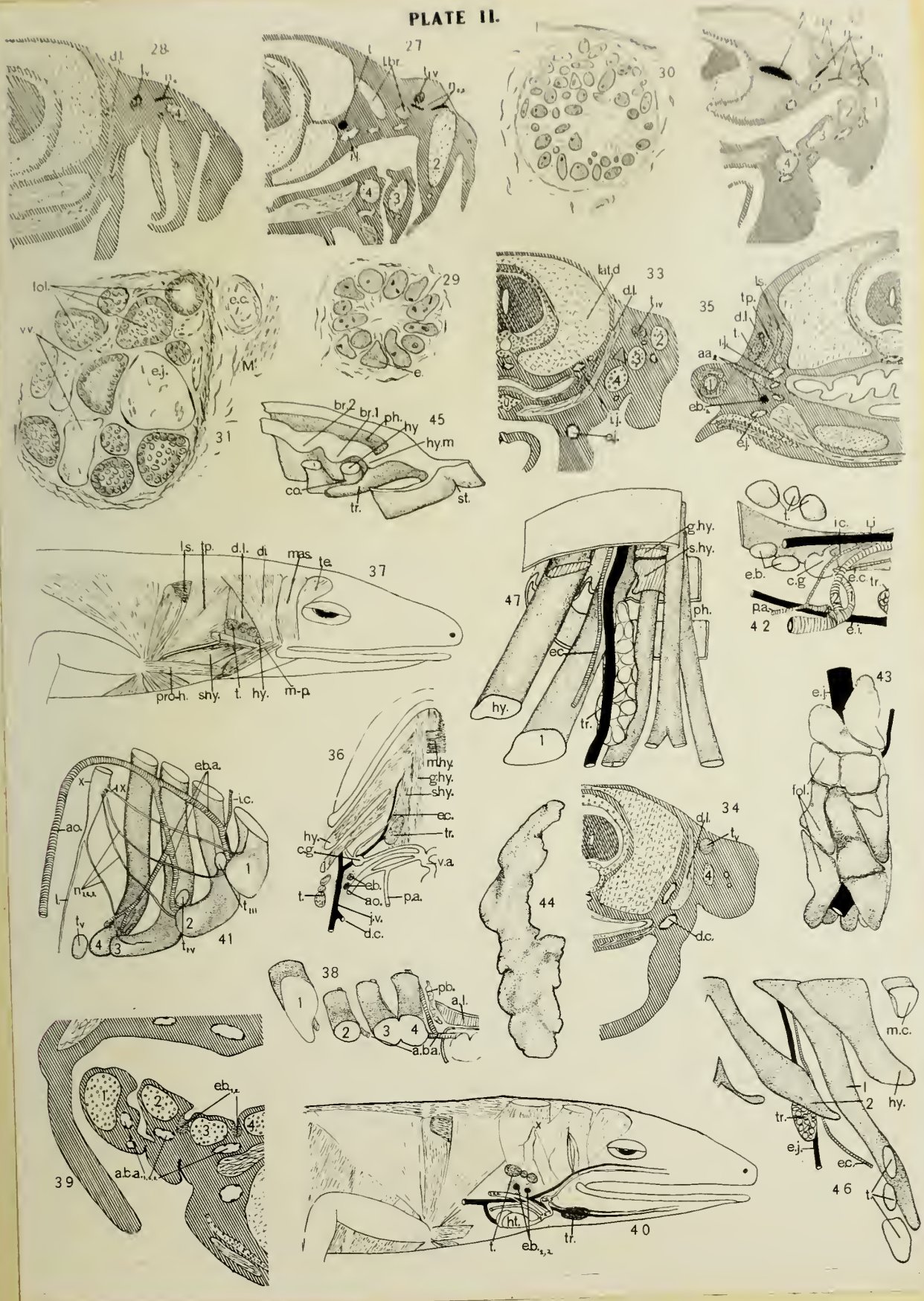
28
d.l.
27
l.br
l.v
30
1
2
3
4
lol.
e.c.
vv.
M.
e.j.
31
29
e.
br.2
br.1
ph.
hy
45
hy.m
co.
tr.
st.
lat.d
33
d.l.
l.v
l.j.
35
ls.
tp.
d.l.
t.
l.j.
aa.
eb.
e.j.
ls.
tp.
d.l.
dl
mas.
te.
37
pro-h.
shy.
t.
hy.
m-p.
g.hy.
s.hy.
ph.
47
ec.
hy.
tr.
1
t.
i.c.
l.j.
e.b.
c.g
e.c
tr.
pa.
42
e.j.
43
e.j.
fol.
eb.a.
x
ix
i.c.
ao.
n.
l.
t.
t.v
t.iv
41
36
m.hy.
g.hy.
shy.
ec.
tr.
hy.
c.g.
v.a.
t.
eb.
ao.
p.a.
j.v.
d.c.
44
34
d.l.
t.v
d.c.
38
pb.
a.l.
a.b.a.
39
eb.
a.b.a.
40
ht.
t.
eb.
tr.
m.c.
1
2
hy.
tr.
e.j.
ec.
46
t.

Library
of the
University of Illinois

UNIVERSITY OF ILLINOIS-URBANA
3 0112 079096985